

Introduction à l'anatomie cérébrale

D. Hasboun
2007 - 2008

Introduction

Traitement de l'information
Névraxe

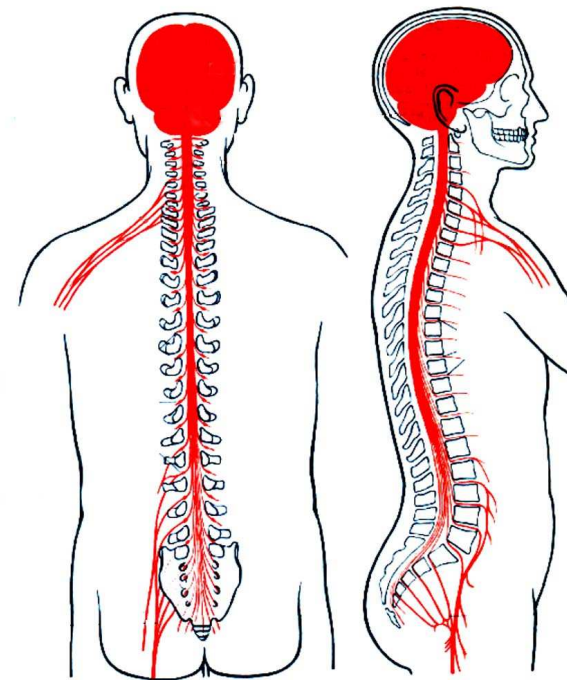
cerveau, Cervelet, tronc
cérébral, moelle spinale

Echelle macroscopique et imagerie
cérébrale

Echelle histologique : neurones,
cellules gliales, méninges.

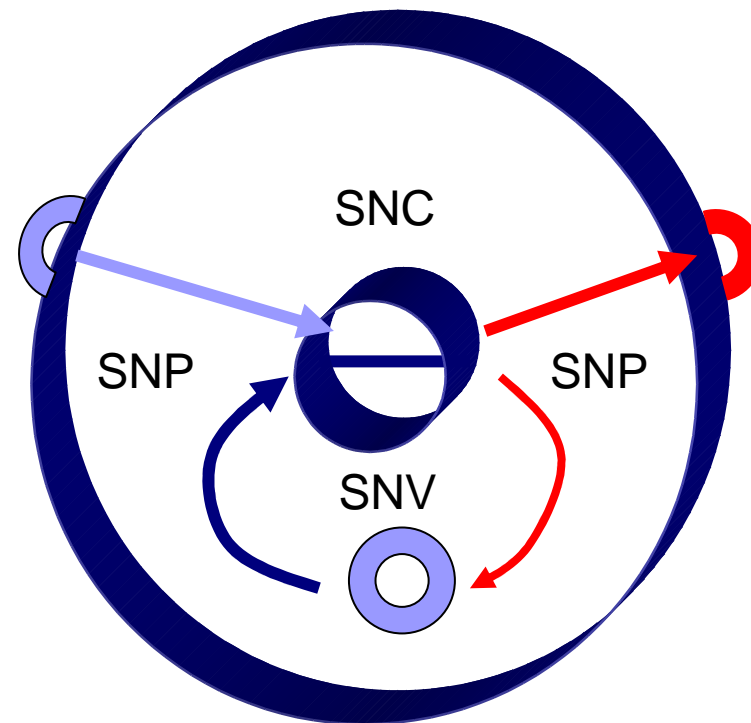
Neurobiochimie,
neurogénétique,
neurobiologie cellulaire

Circuit neuronaux



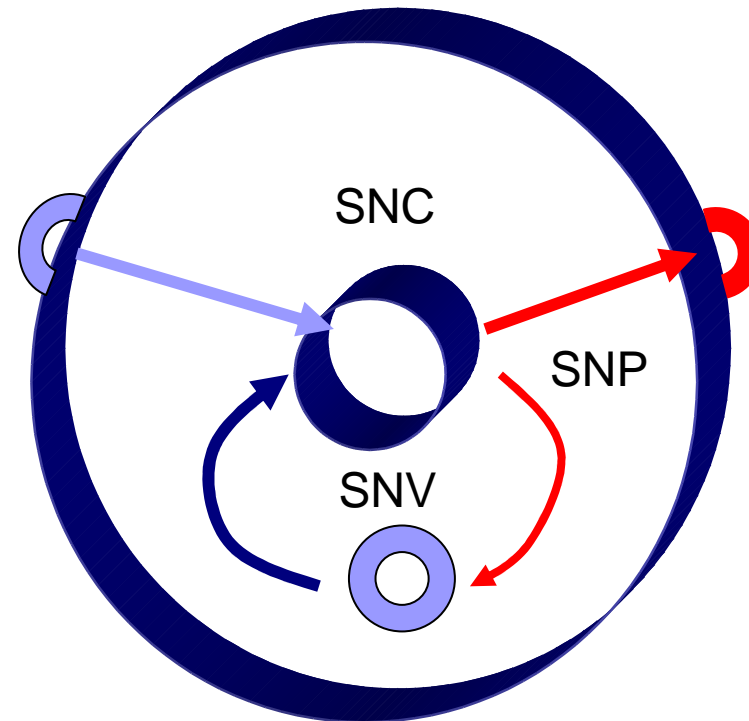
Les grandes fonctions du système nerveux

- Réception
- Conduction
- Intégration
- (Conduction)
Réponse



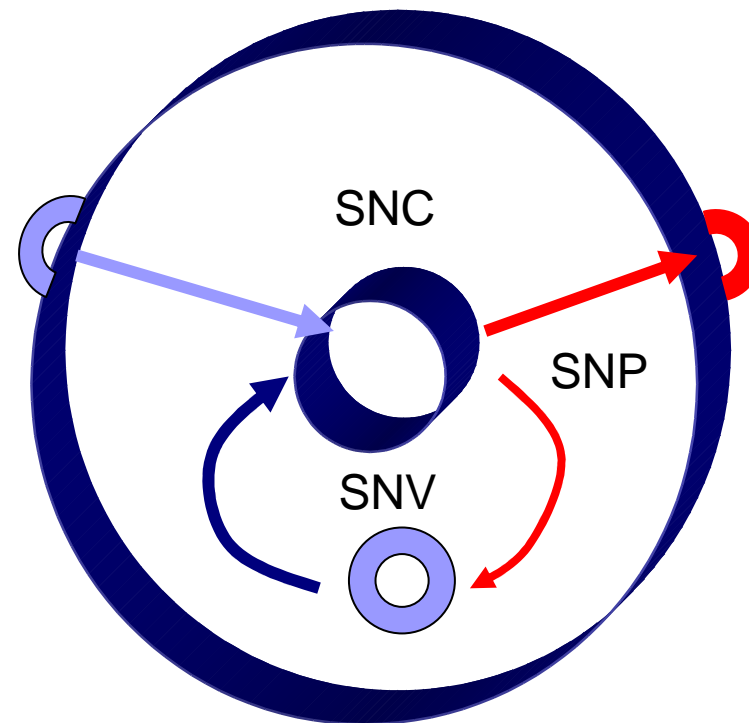
Trois subdivisions anatomiques

- **Systeme nerveux central**
- **Systeme nerveux peripherique**
 - Afférences
 - efférences
- **SN végétatif (autonome)**
 - Sympathique
 - para sympathique



Deux subdivisions fonctionnelles

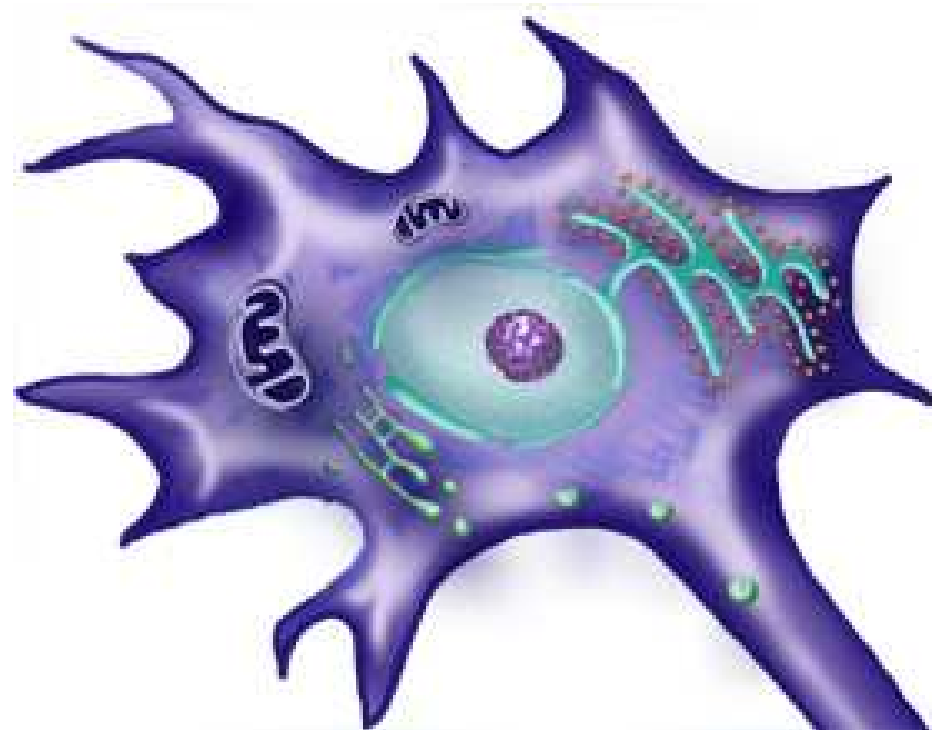
- **Systeme somatique**
- **Systeme viscéral**



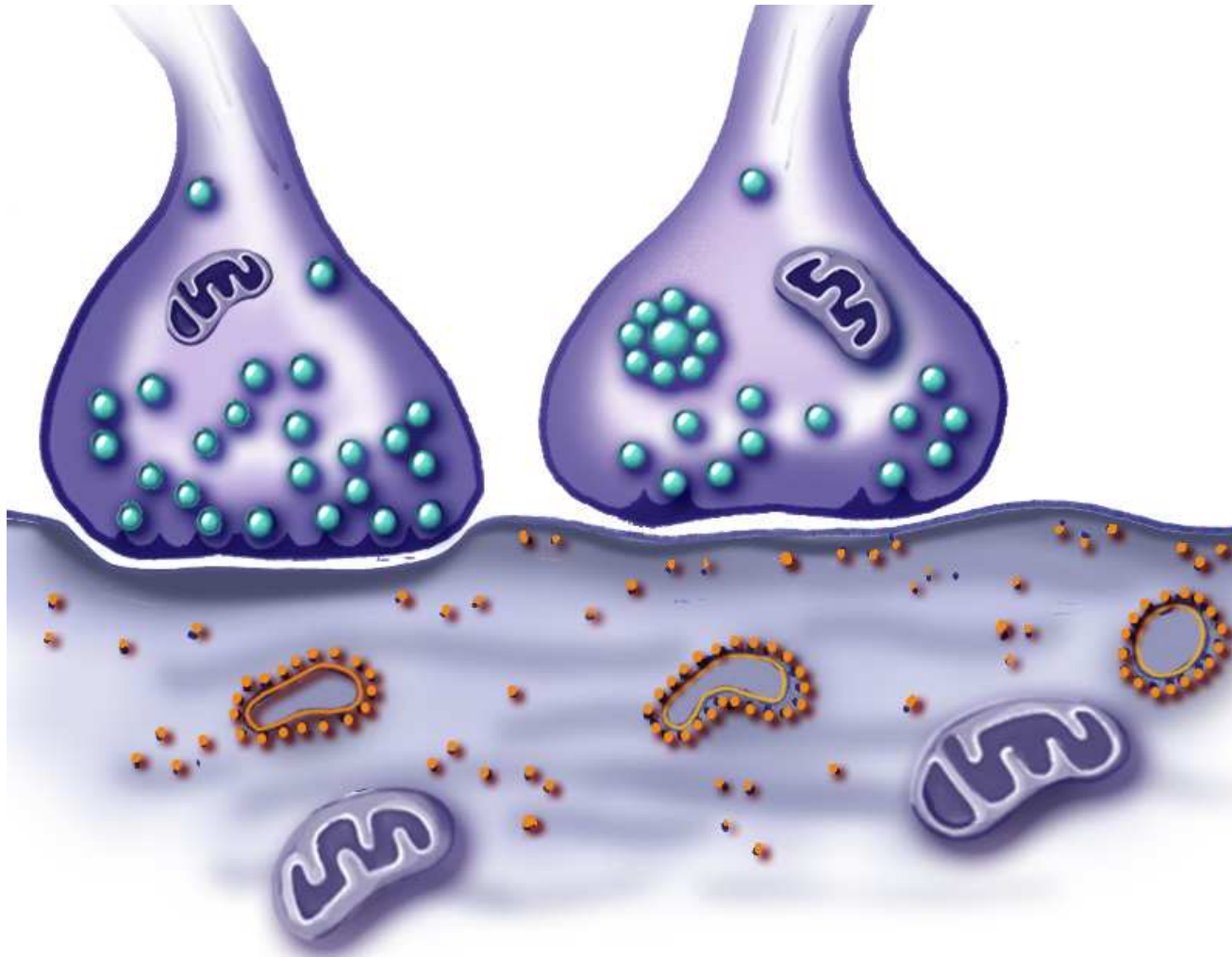
Le neurone

- **Introduction**
- **Le soma ou corps cellulaire:**
- **Prolongements :**
 - **dendrites :**
 - **Axones :**
*prolongements longs
(conduction de la
réponse)*

□ **liens**

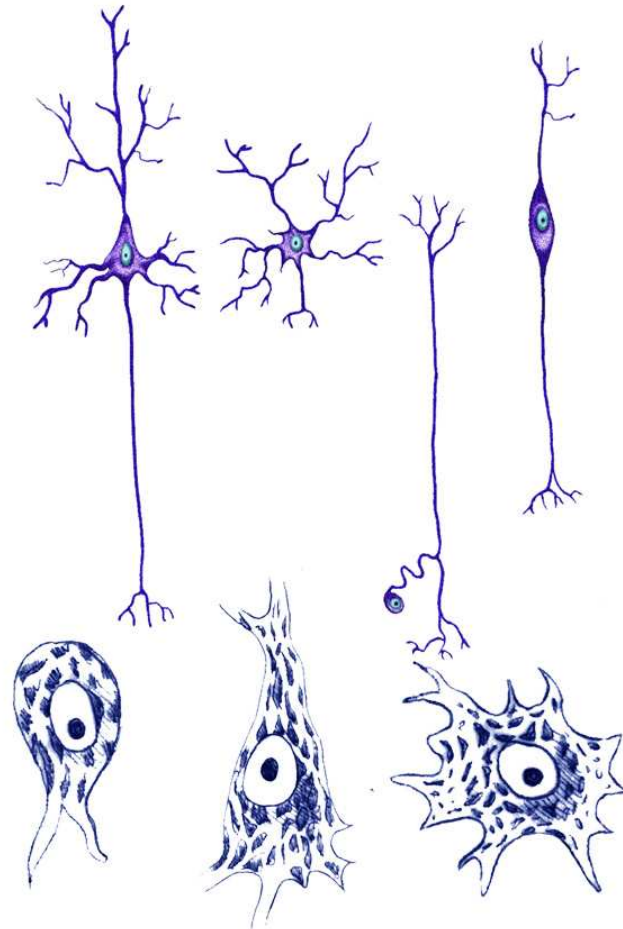
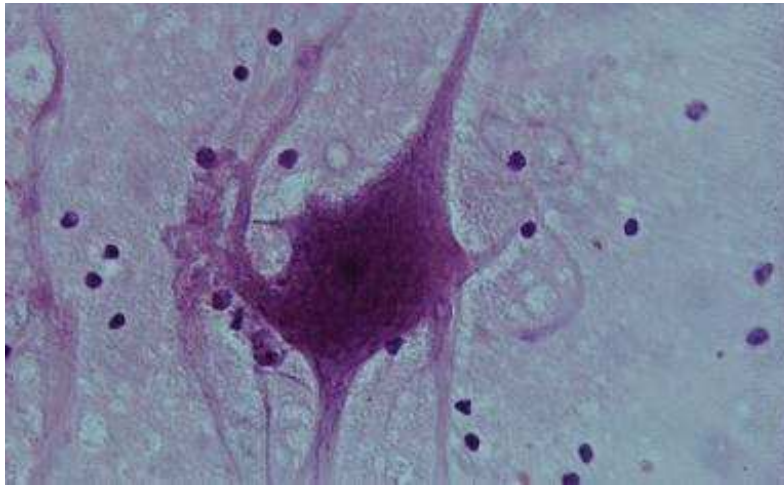


Synapses



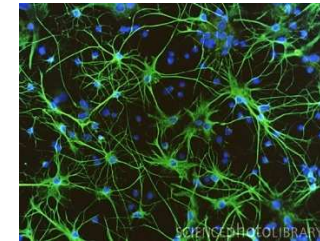
Classification des neurones

- selon le corps cellulaire
- selon l'axone



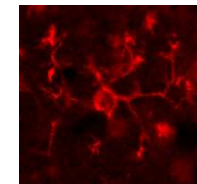
Glie centrale

□ **Les astrocytes (macroglie)**

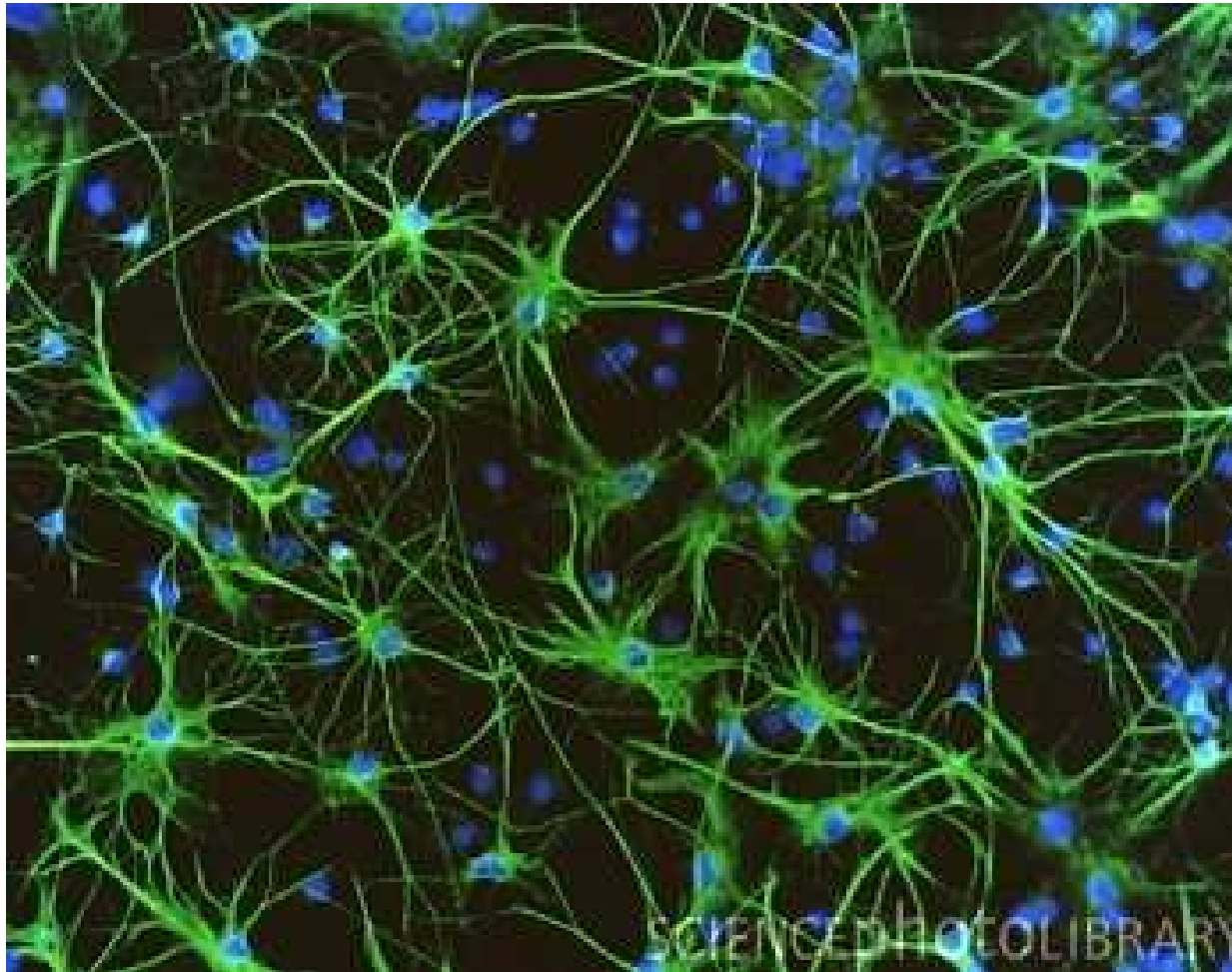


□ **Les oligodendrocytes (oligodendroglie)**

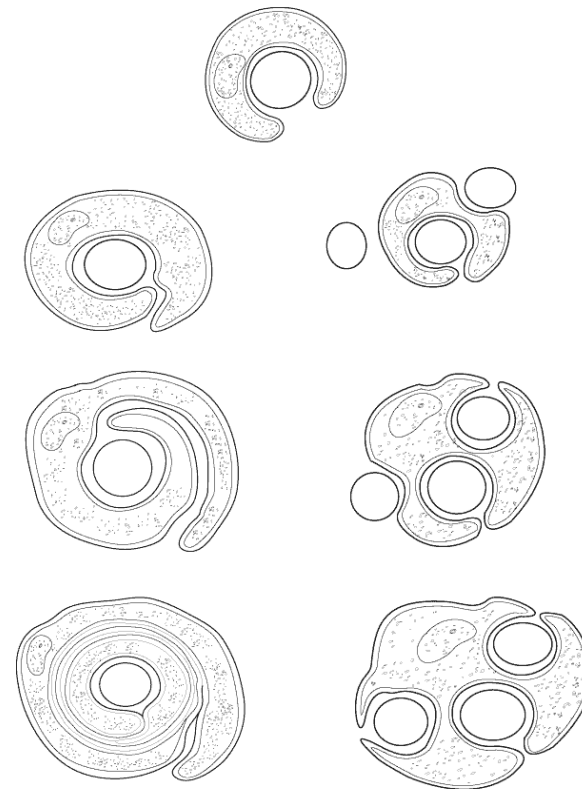
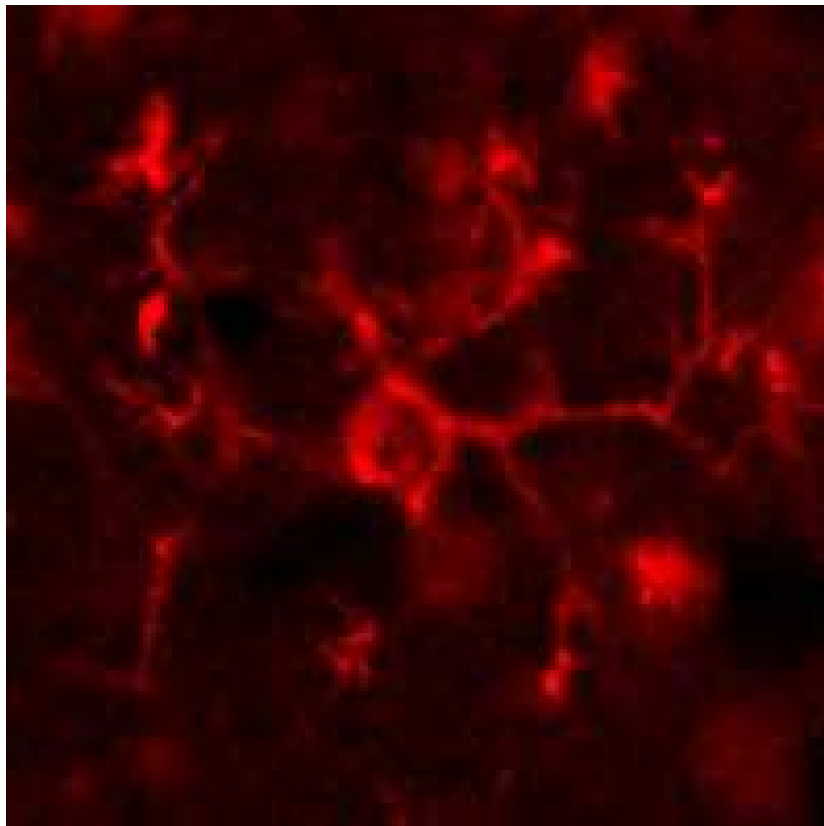
□ **Les microgliocytes (microglie)**



Astrocytes

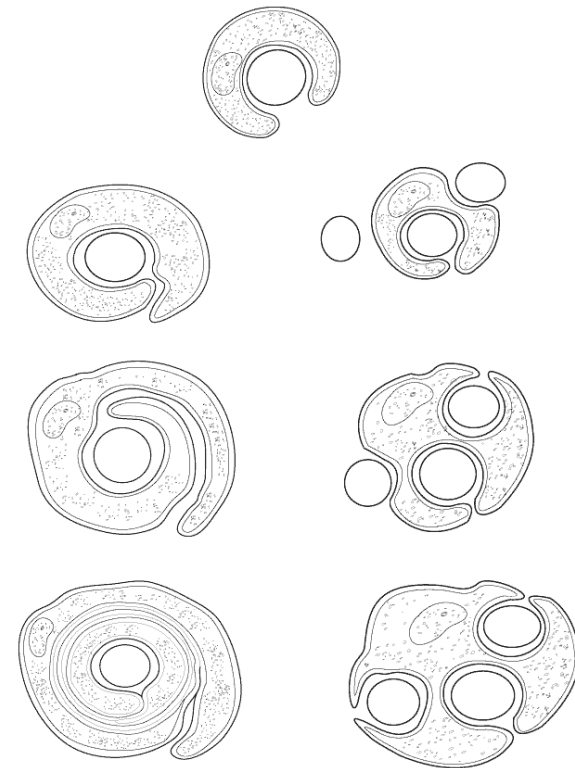
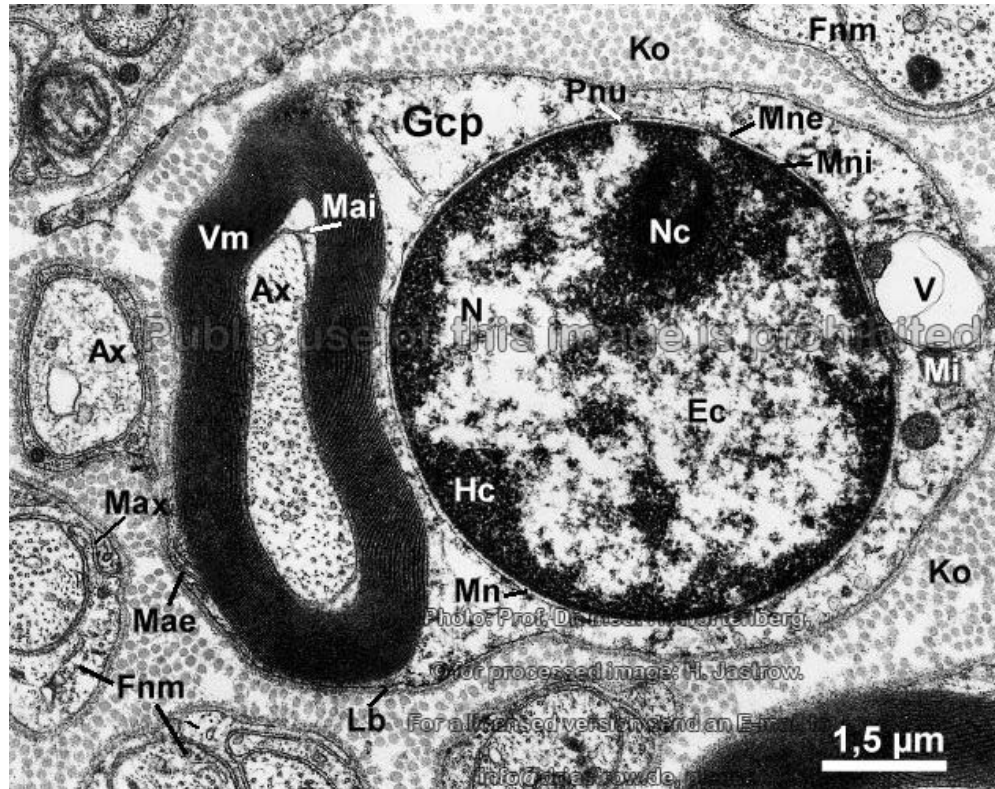


Oligodendrocytes

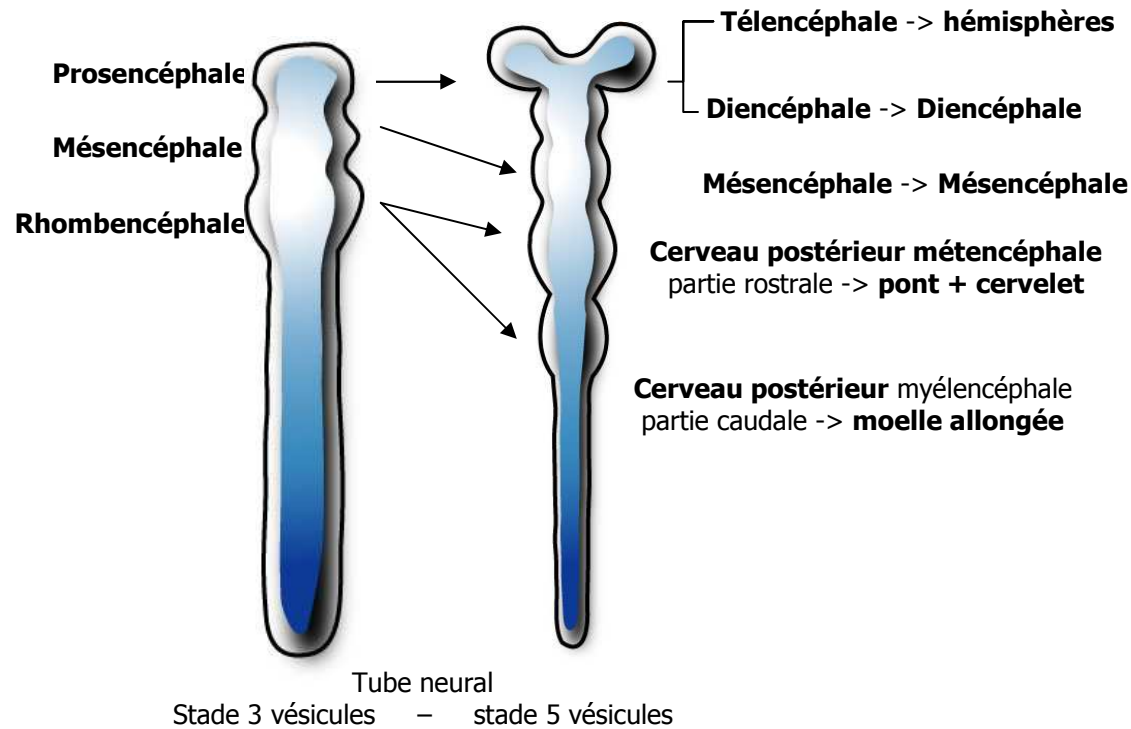


Glie périphérique

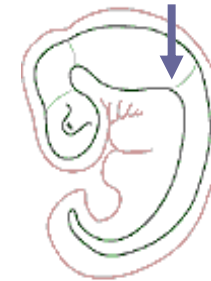- cellules de Schwann



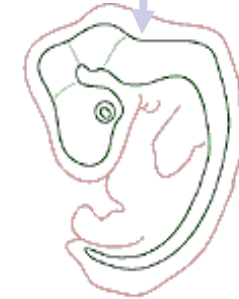Embryologie



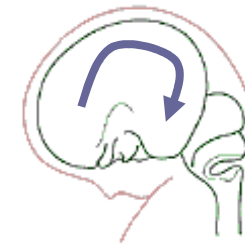
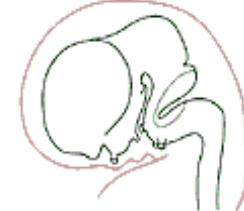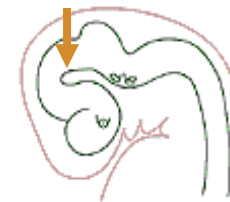Courbure cervicale



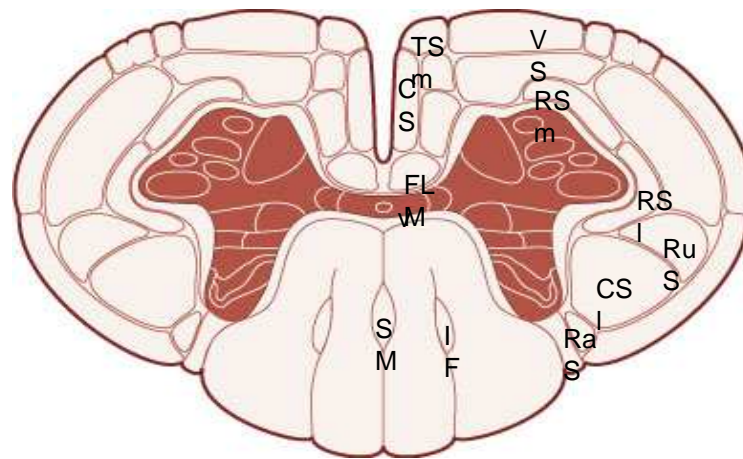
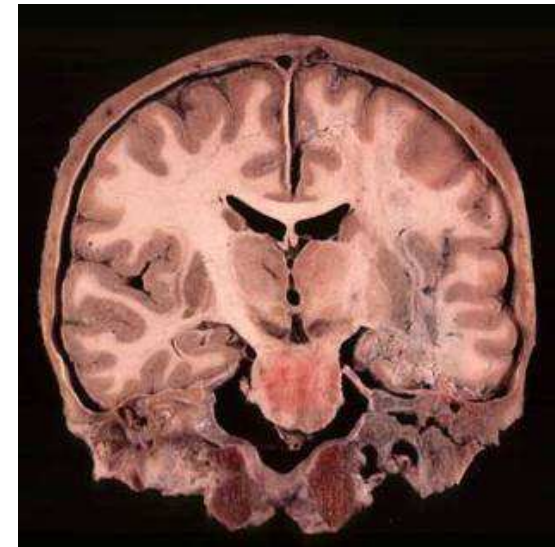
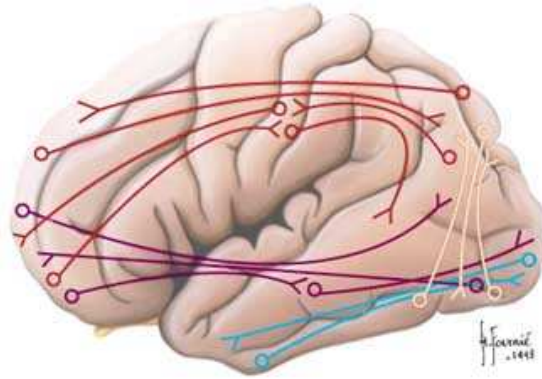
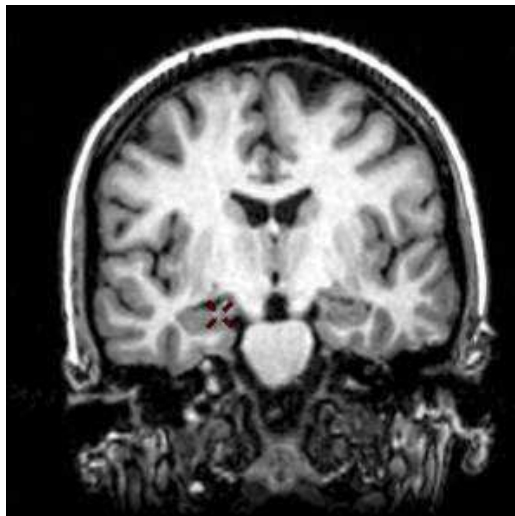
Courbure pontique



Courbure mésencéphalique

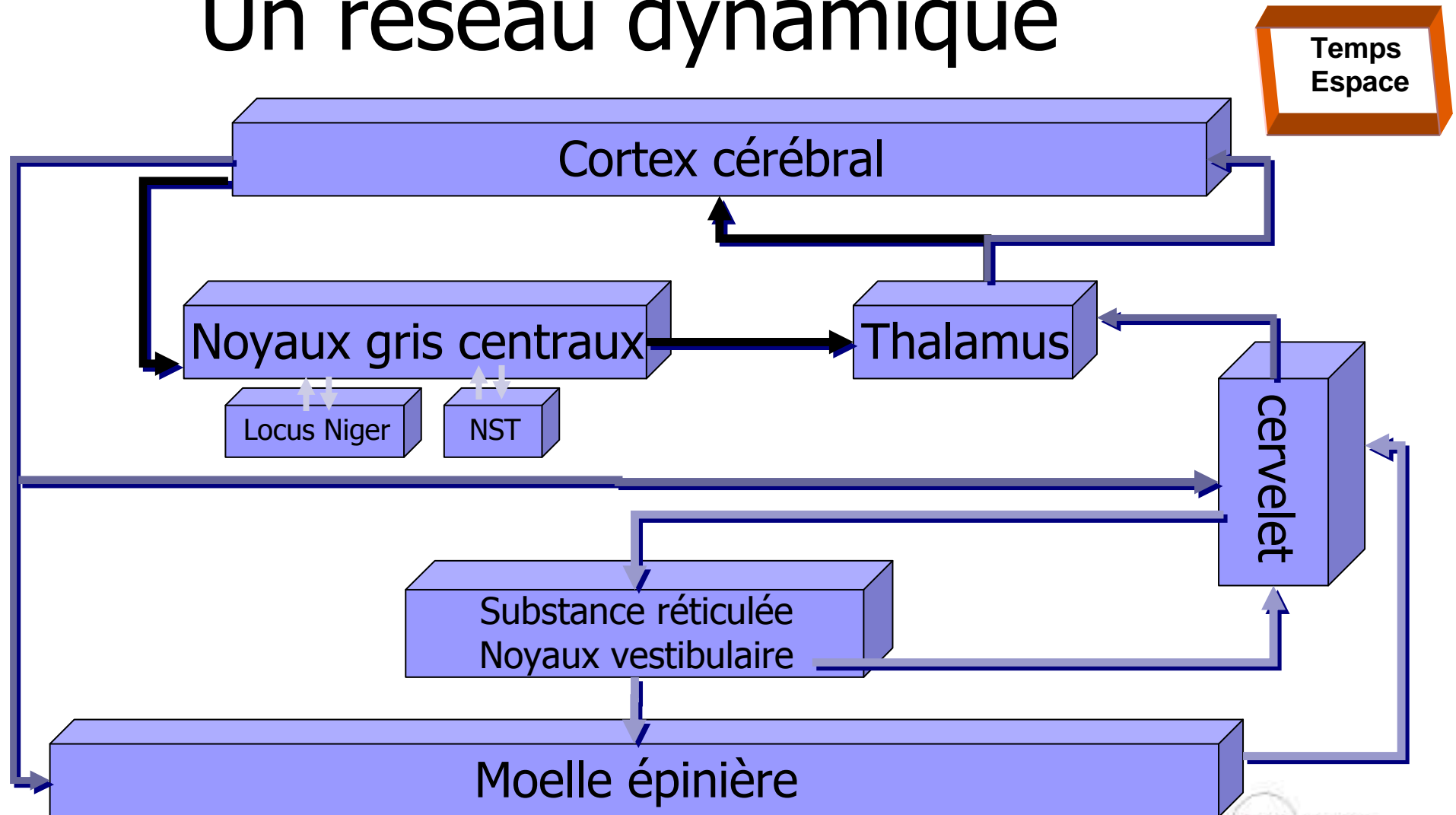


Substance blanche et grise

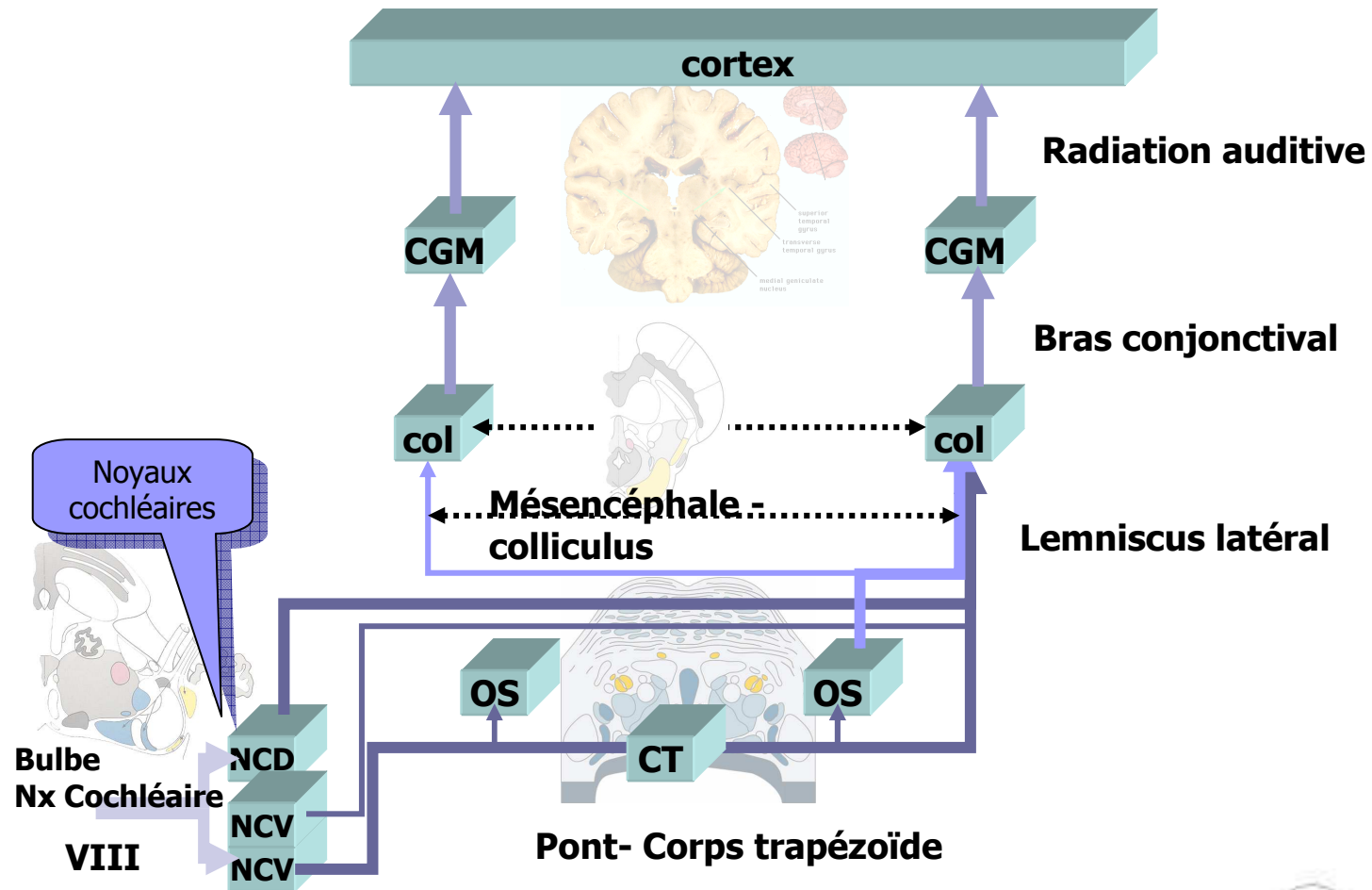


D. Hasboun 2007-2008

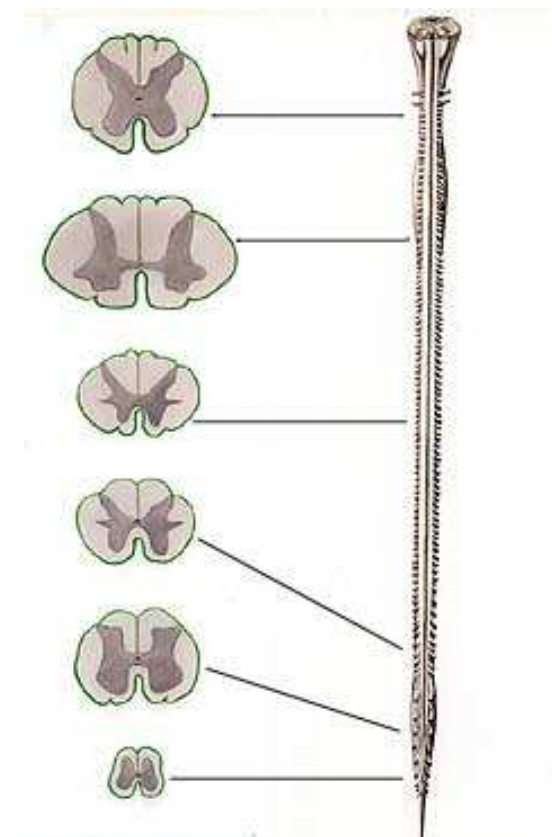
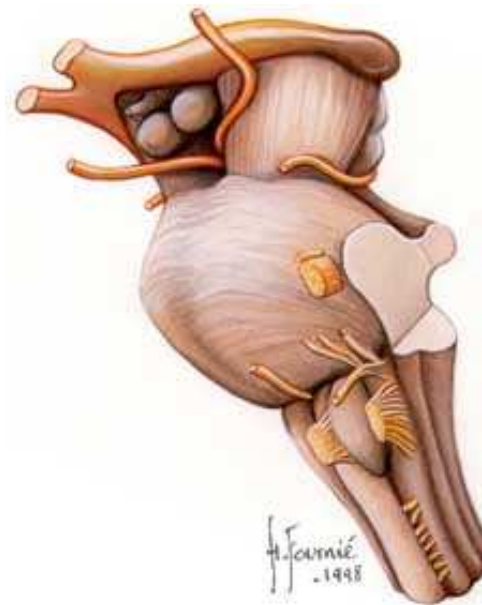
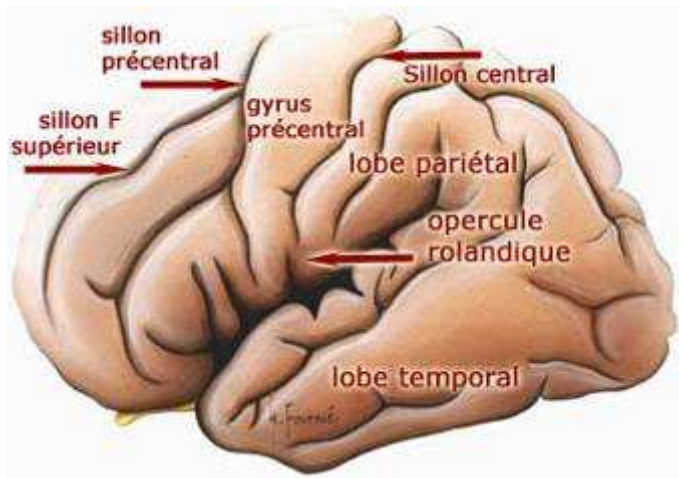
Un réseau dynamique



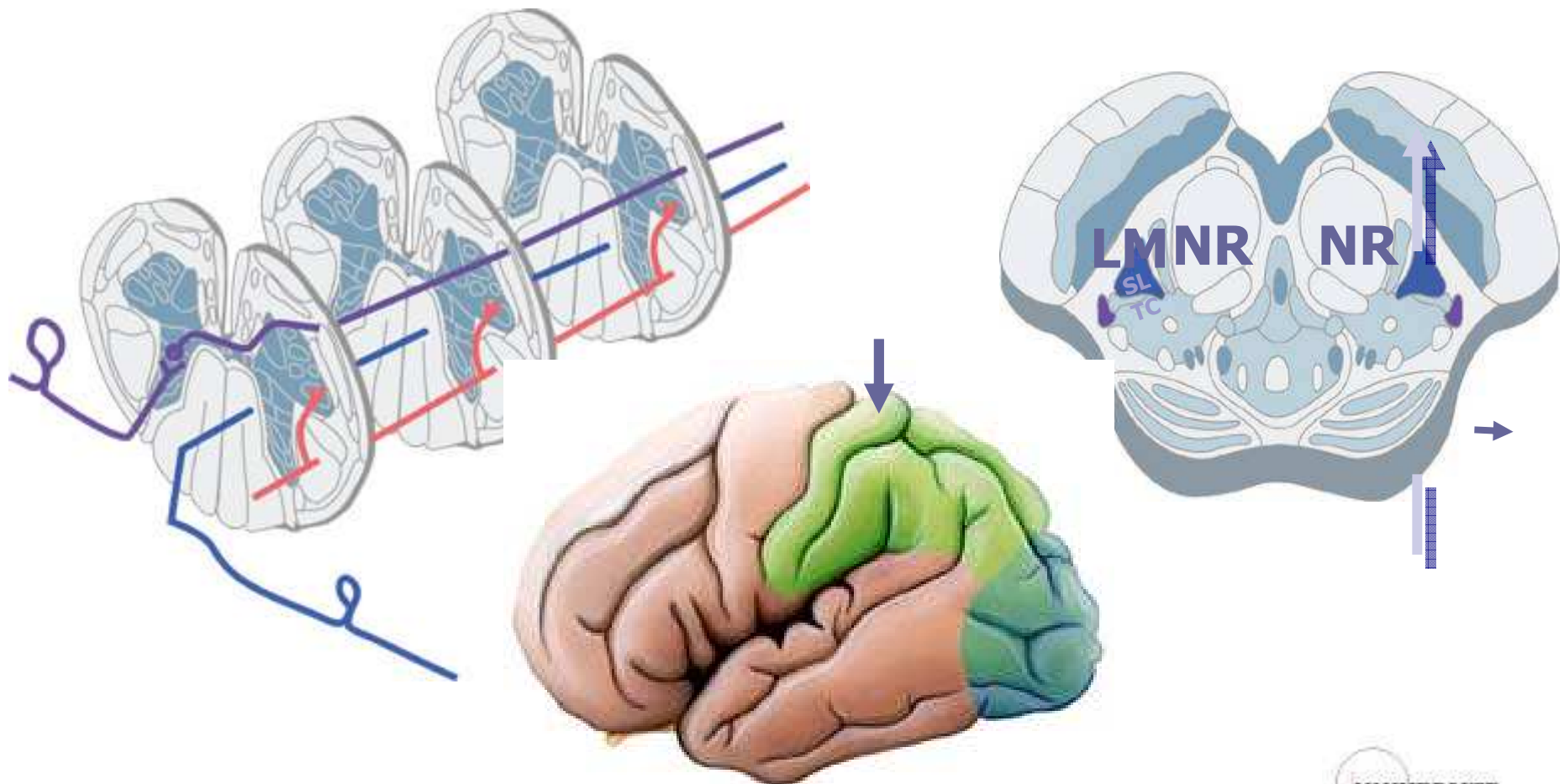
Un traitement série / parallèle



Une hiérarchie anatomo-fonctionnelle



Traitement distribué



Enveloppes : os et méninges

■ Feuilletts

□ Pachyméninge

■ Dure mère →

□ Leptoméninge

■ Arachnoïde →

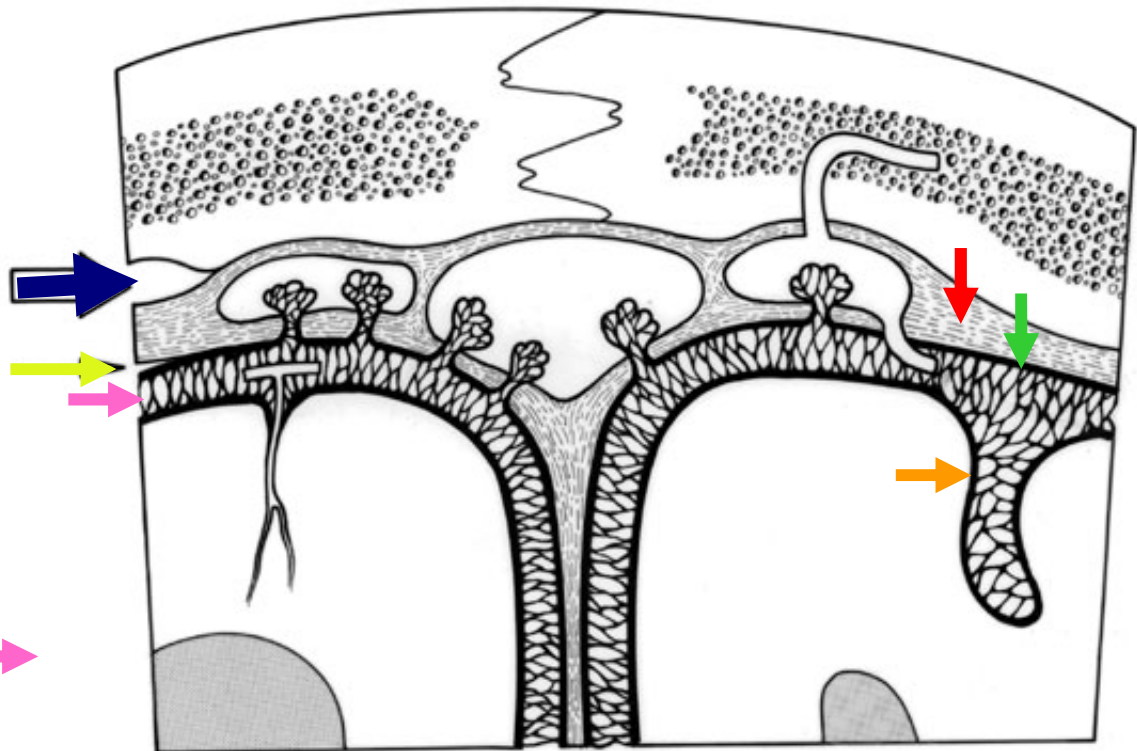
■ Pie mère →

■ Espaces

□ Extra-dural →

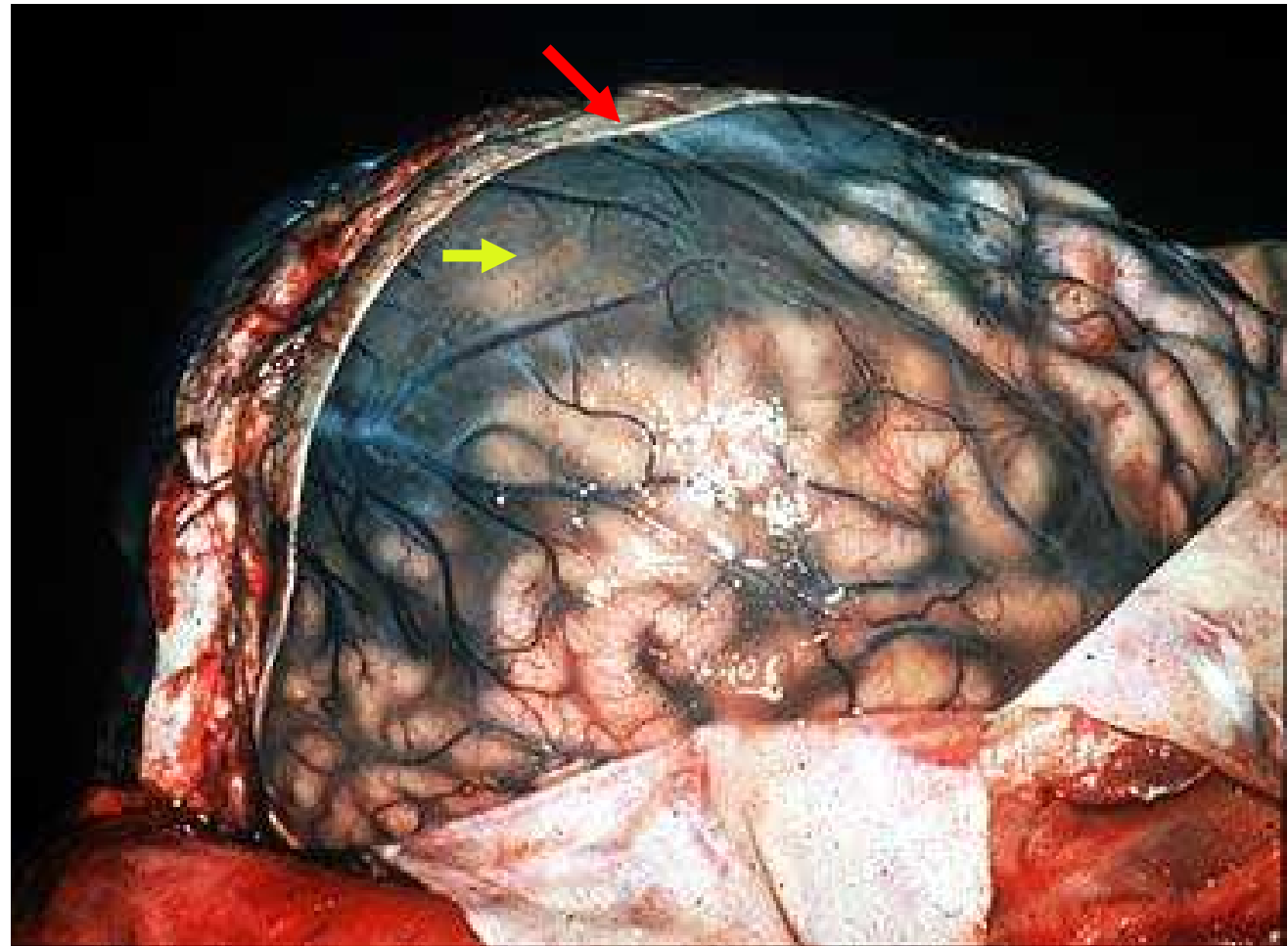
□ Sous-dural →

□ Sous-arachnoïdien →



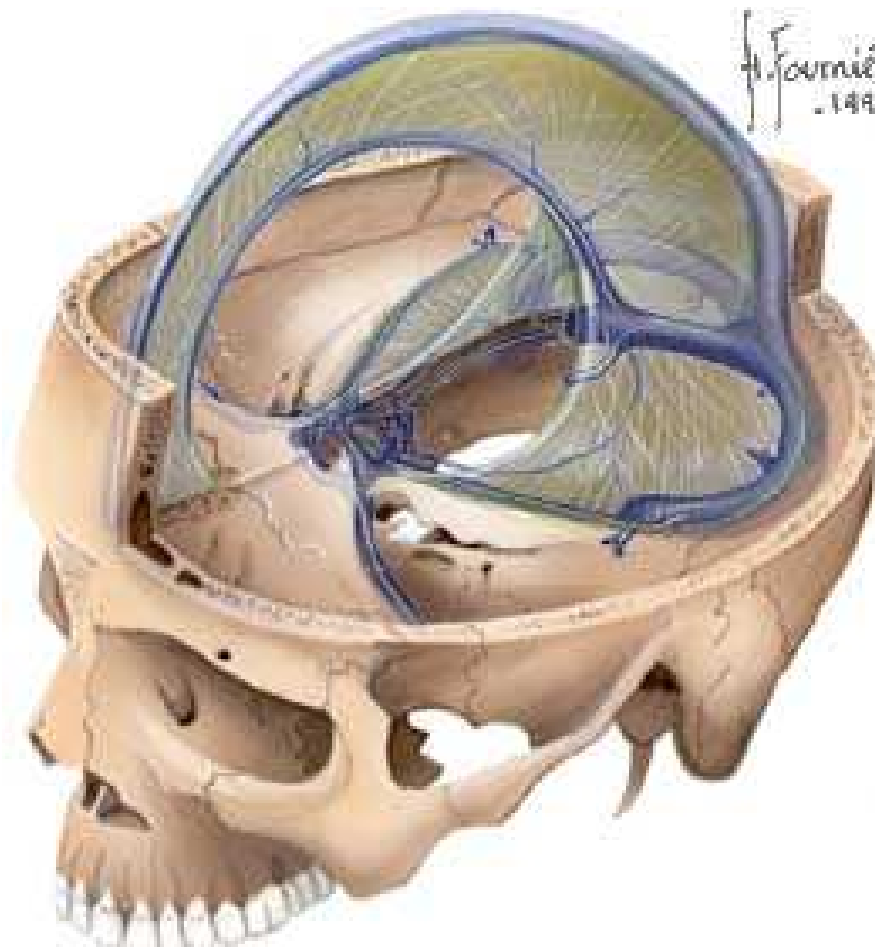
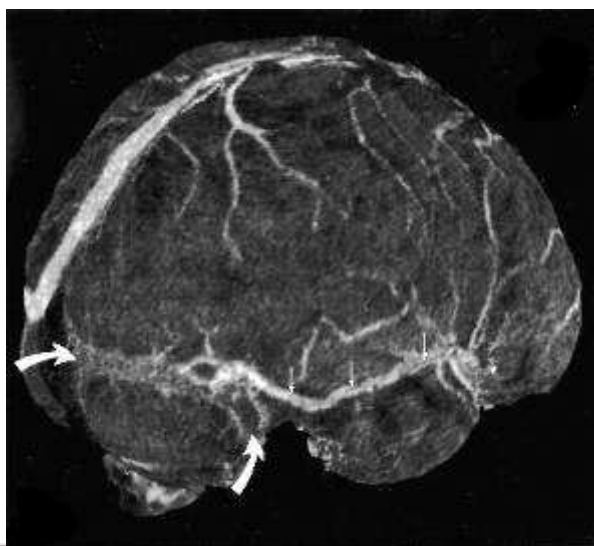
Méninges

- Pachyméninge
 - Dure mère →
- Leptoméninge
 - Arachnoïde →
 - Pie mère



Sinus veineux : drainage veineux

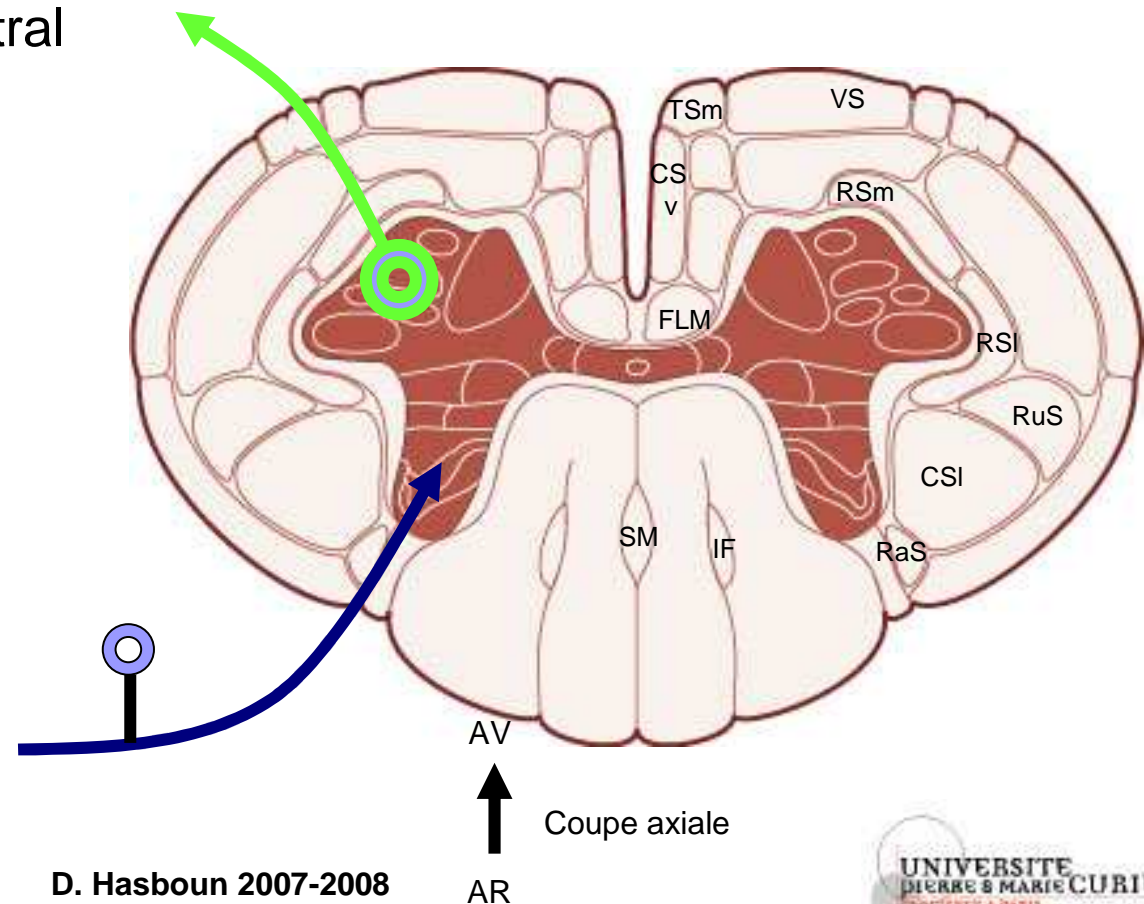
- Groupe postéro-supérieur
- Groupe antéro-inférieur



Voies descendantes

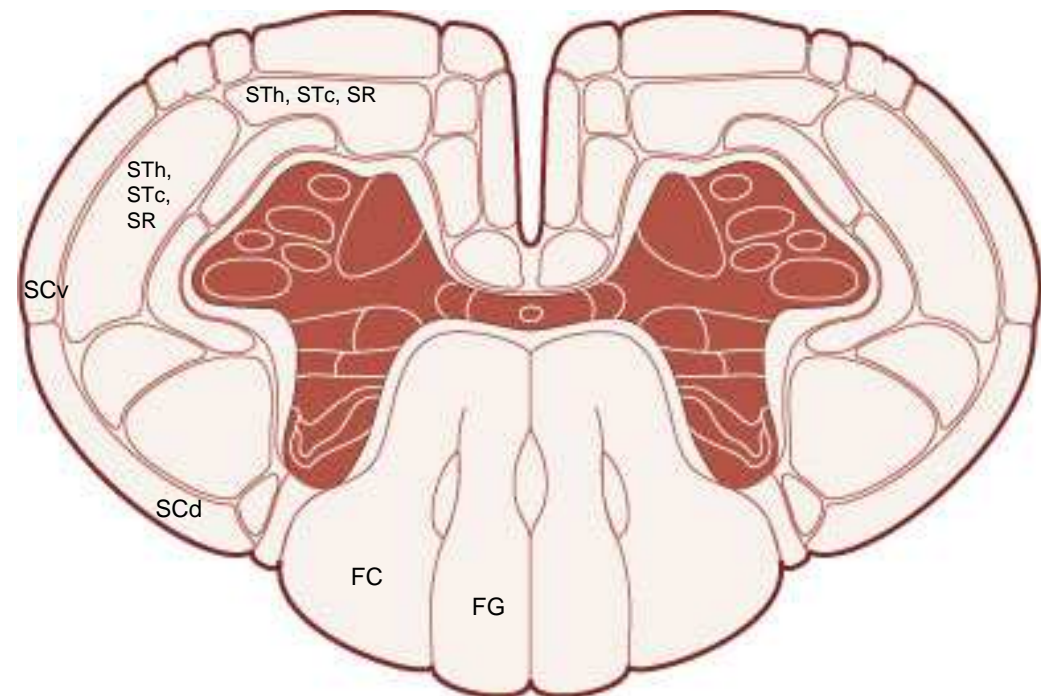
- CSI : corticospinal latéral
- CSv : corticospinal ventral
- RuS : rubrospinal
- VS : vestibulospinal
- RSm : réticulospinal médial
- FLM : Fx Lg Médial

- RaS : raphé-spinal
- IF : interfasciculaire
- TSm : tectospinal médial
- SM : septomarginal



Voies ascendantes

- FG : Faisceau gracile
- FC : Faisceau cunéiforme
- STh : spinothalamique
- SR spinoréticulaire
- SCd : spinocérébelleux dorsal
- SCv : spinocérébelleux ventral
- STc : spinotectal



AV

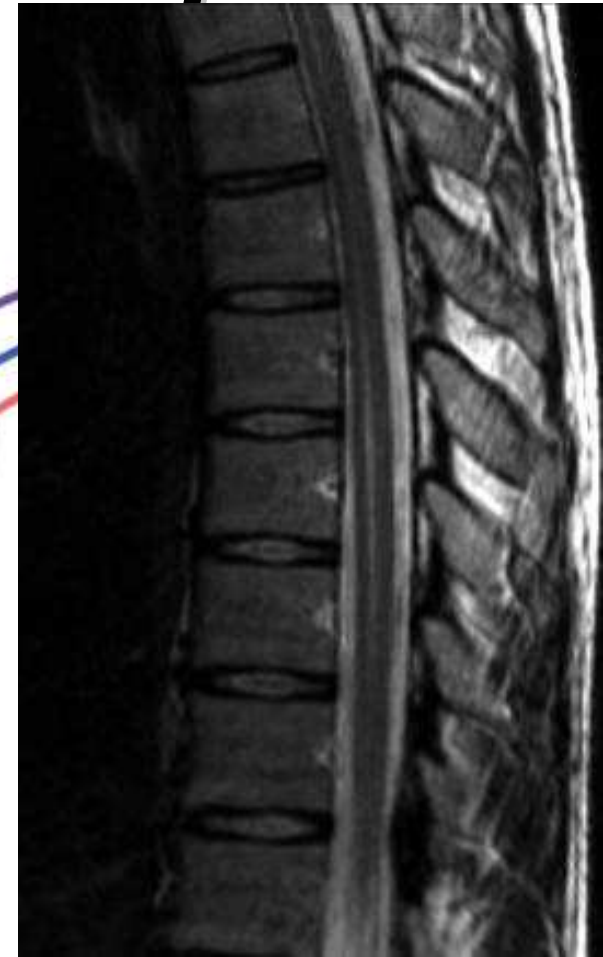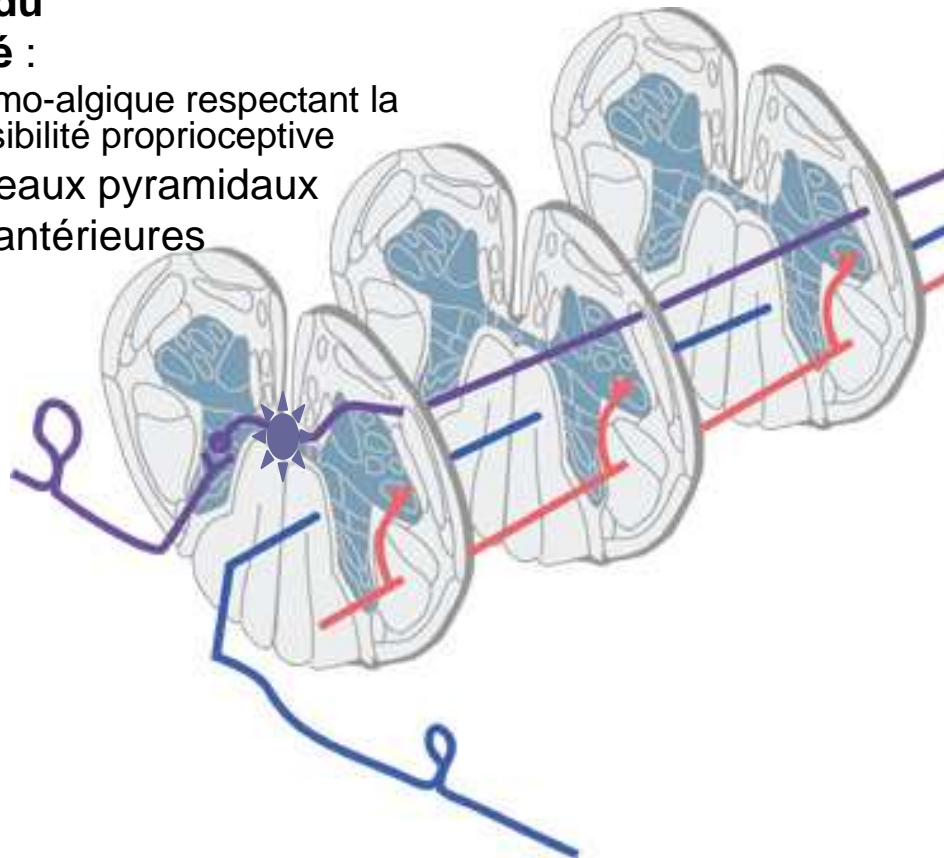


Coupe axiale

AR

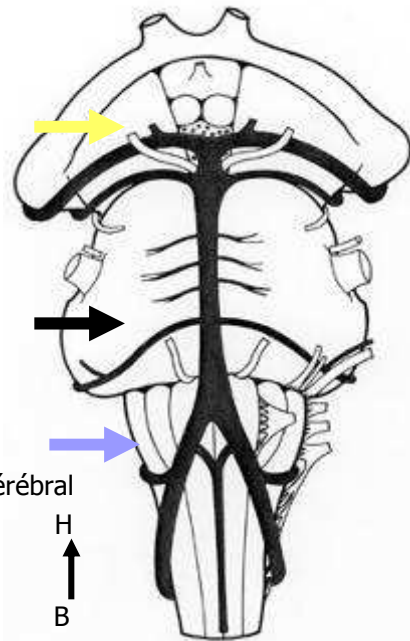
syndrome centro-médullaire, syndrome syringomyélique

- déficit sensitif
- **suspendu**
- **dissocié :**
 - thermo-algique respectant la sensibilité proprioceptive
- +/- faisceaux pyramidaux
- Cornes antérieures



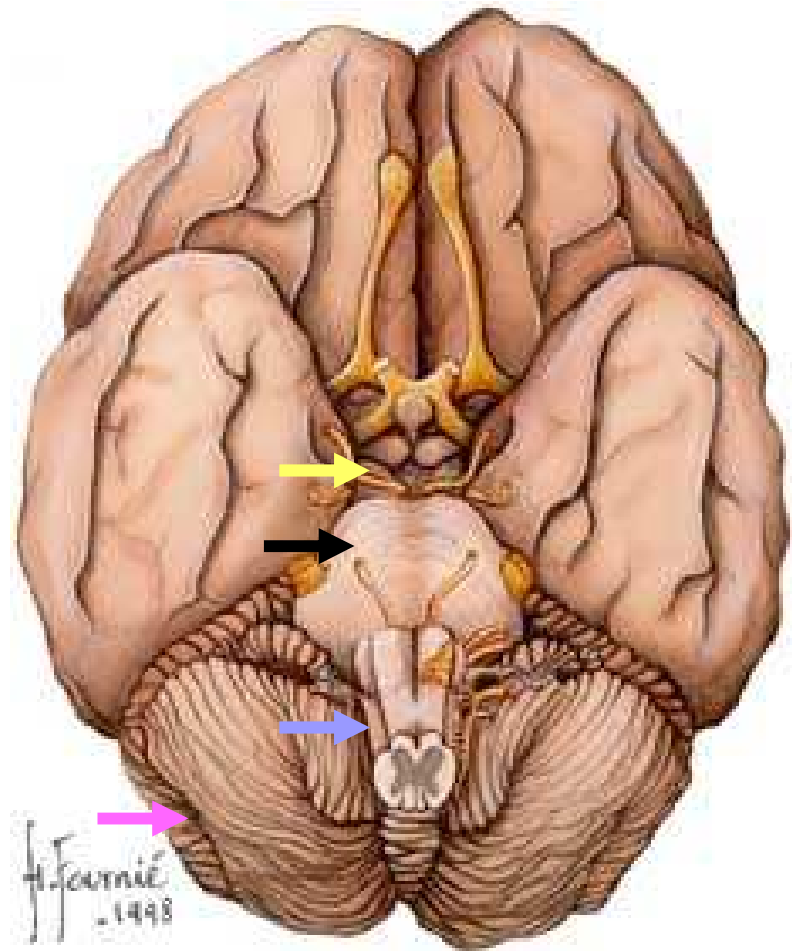
Tronc cérébral : 3 étages

- Moelle allongée (bulbe rachidien) →
- Pont (protubérance annulaire) →
- Mésencéphale →
- Cervelet en arrière →



Vue antérieure du tronc cérébral

H
↑
B

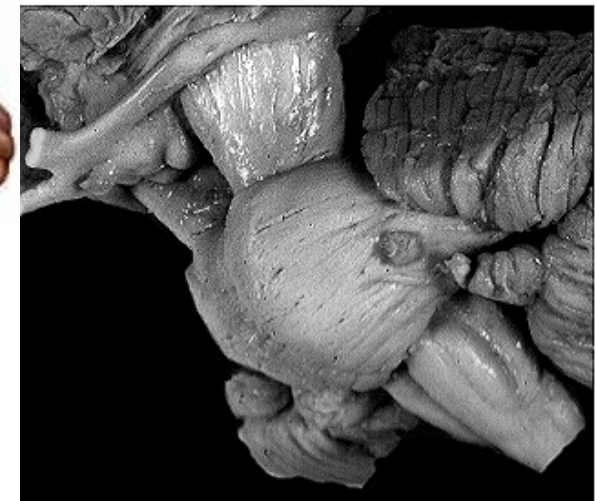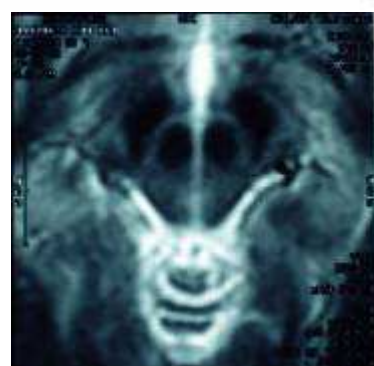
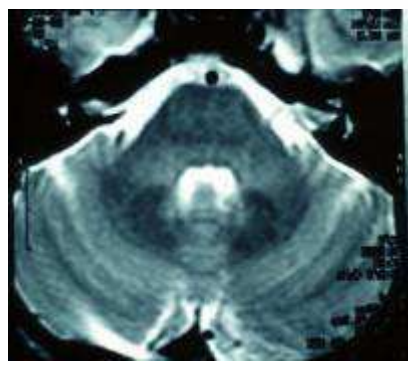
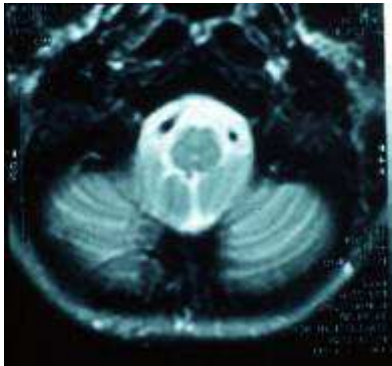
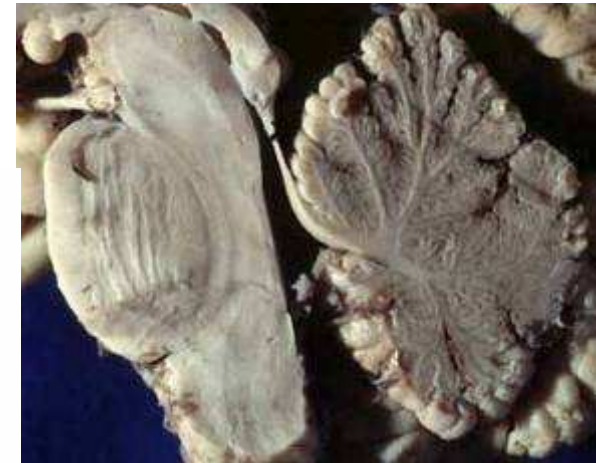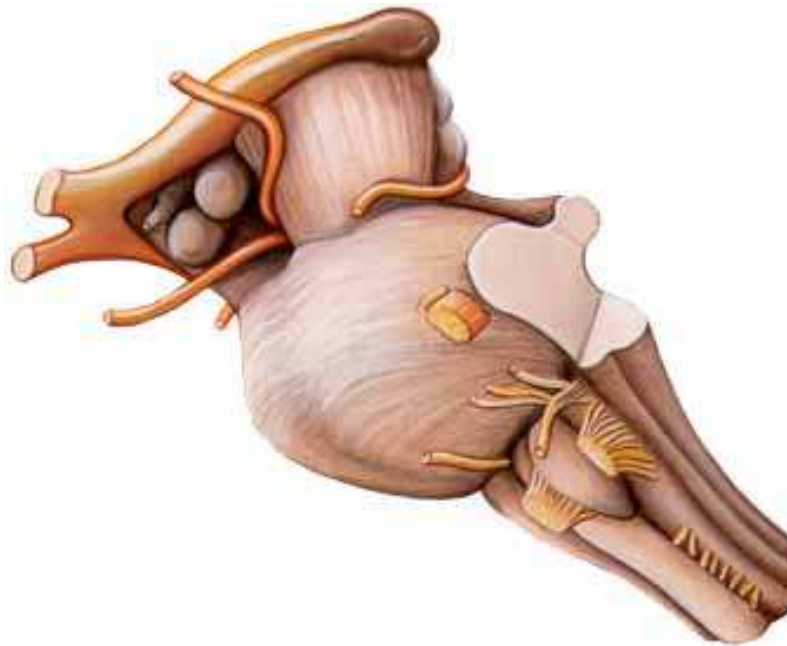


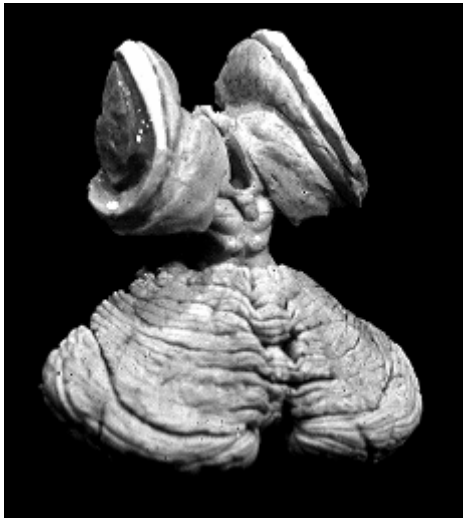AV
↑
AR

D. Hasboun 2007-2008

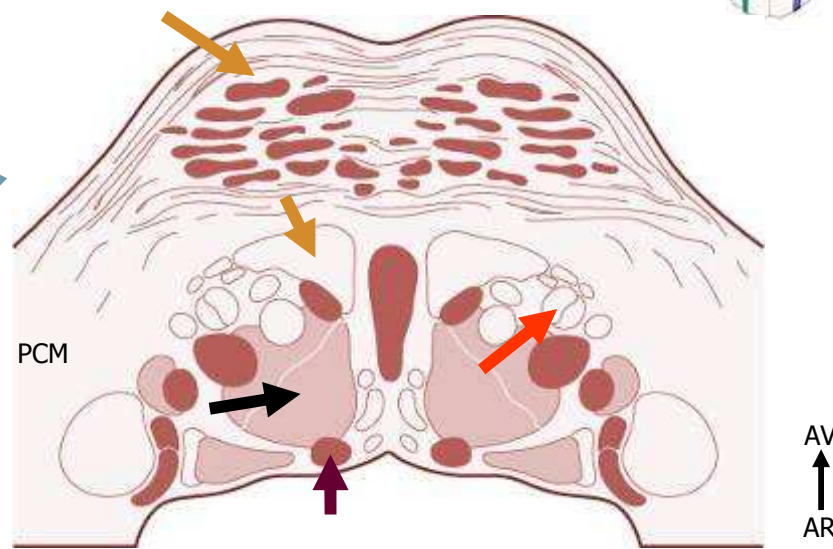
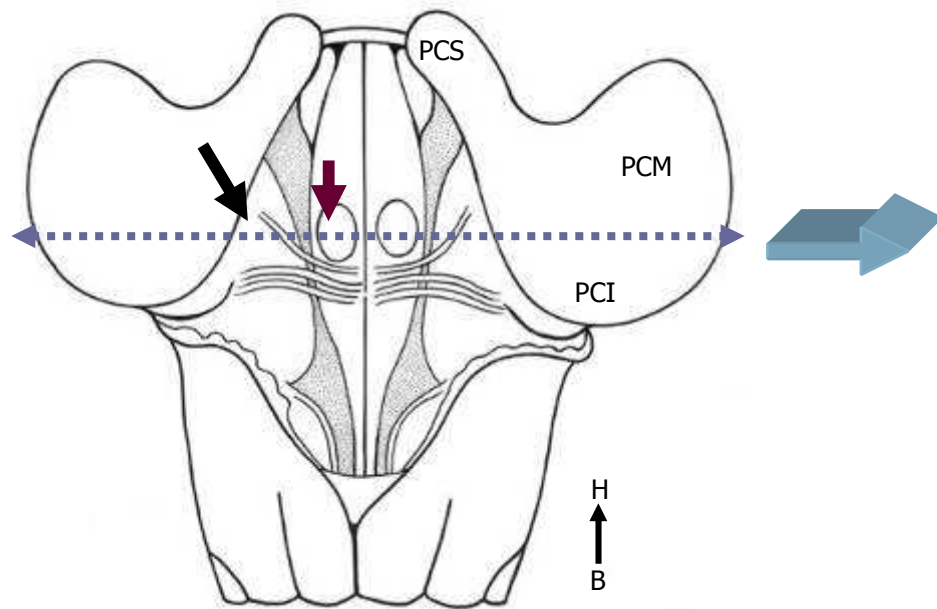
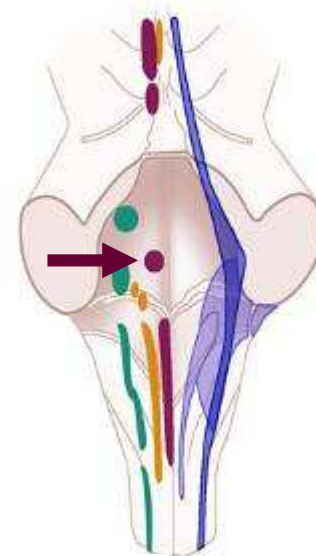
Vue inférieure du cerveau

Tronc cérébral



Tronc cérébral

- Nx N Crâniens →
- Grandes voies →
- Réticulée →
- Nx propres →

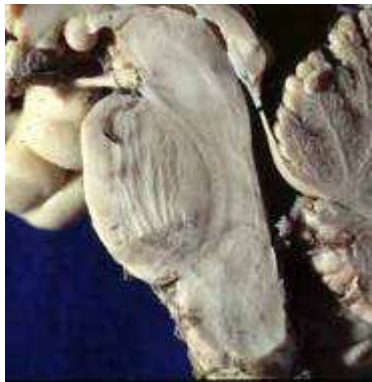

Coupe axiale du pont

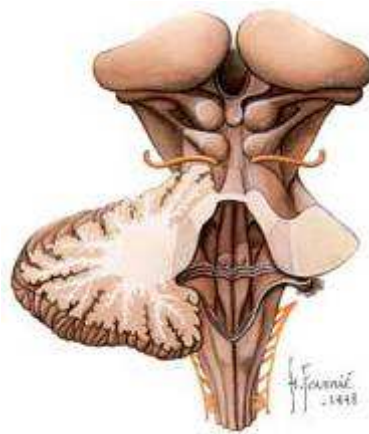Vue postérieure du tronc cérébral

Mésencéphale : colliculi

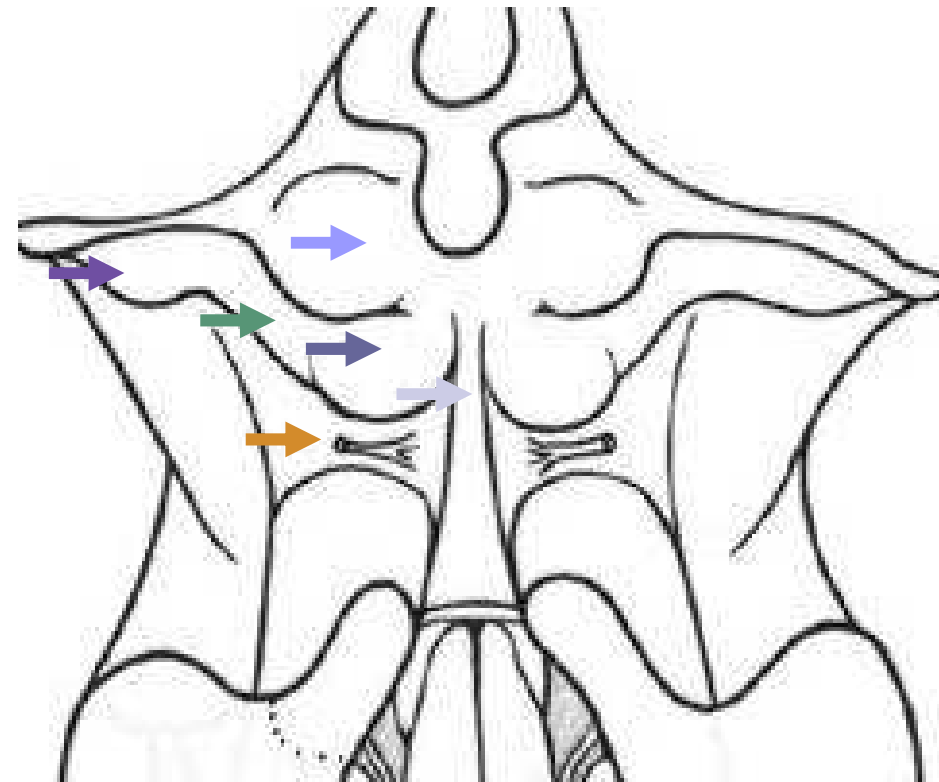- colliculus inférieurs →
- Bras conjonctival inférieur →
- Corps géniculé médial →
- colliculus supérieurs →
- BCS, CGLatéral
- frein du voile médullaire supérieur →
- nerf trochléaire →



Coupe sagittale

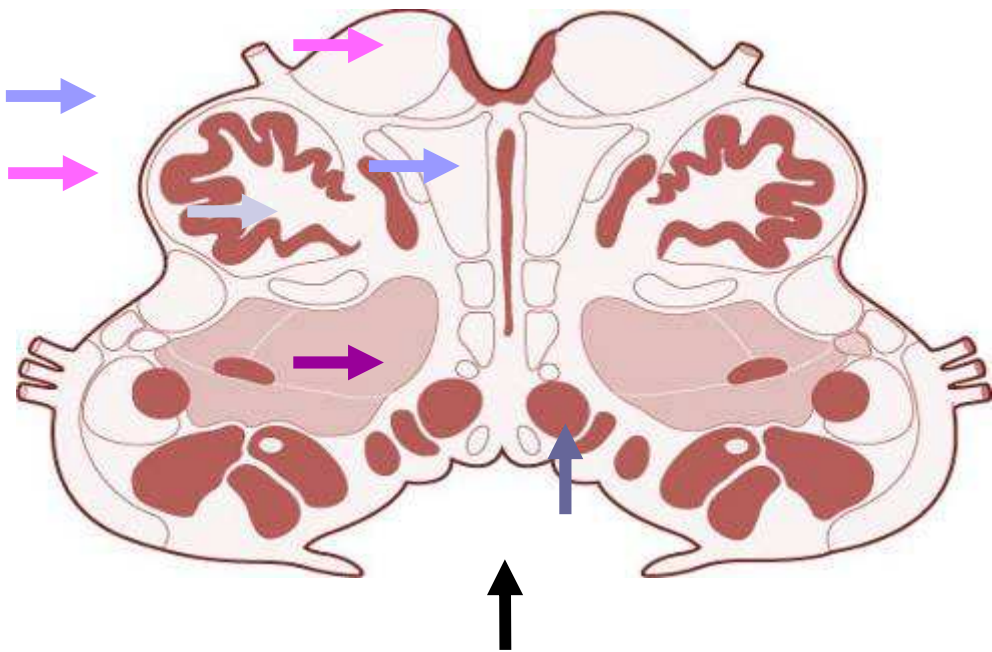


H
↑
vues postérieures du TC
B



Tronc cérébral : contenu

- Voies ascendantes (sensibilité) →
- Voies descendantes (motricité) →
- noyaux des nerfs crâniens →
- noyaux propres →
- substance réticulée →
- Cavité épendymaire →
 - Quatrième ventricule.

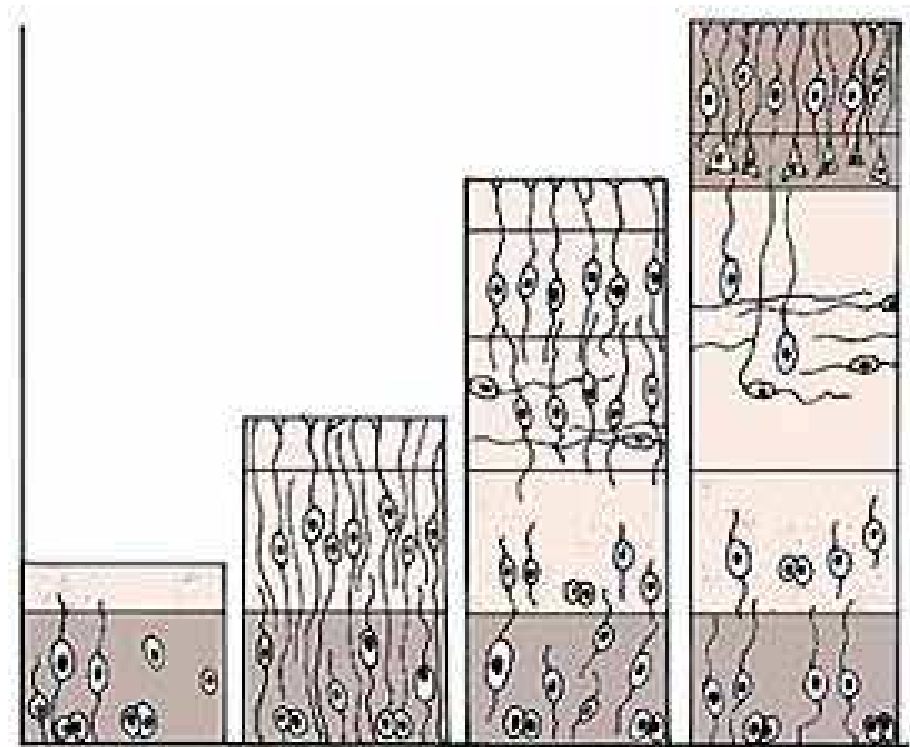


AV
↑
AR

Coupe axiale de la moelle allongée

Cortex cérébral : Développement

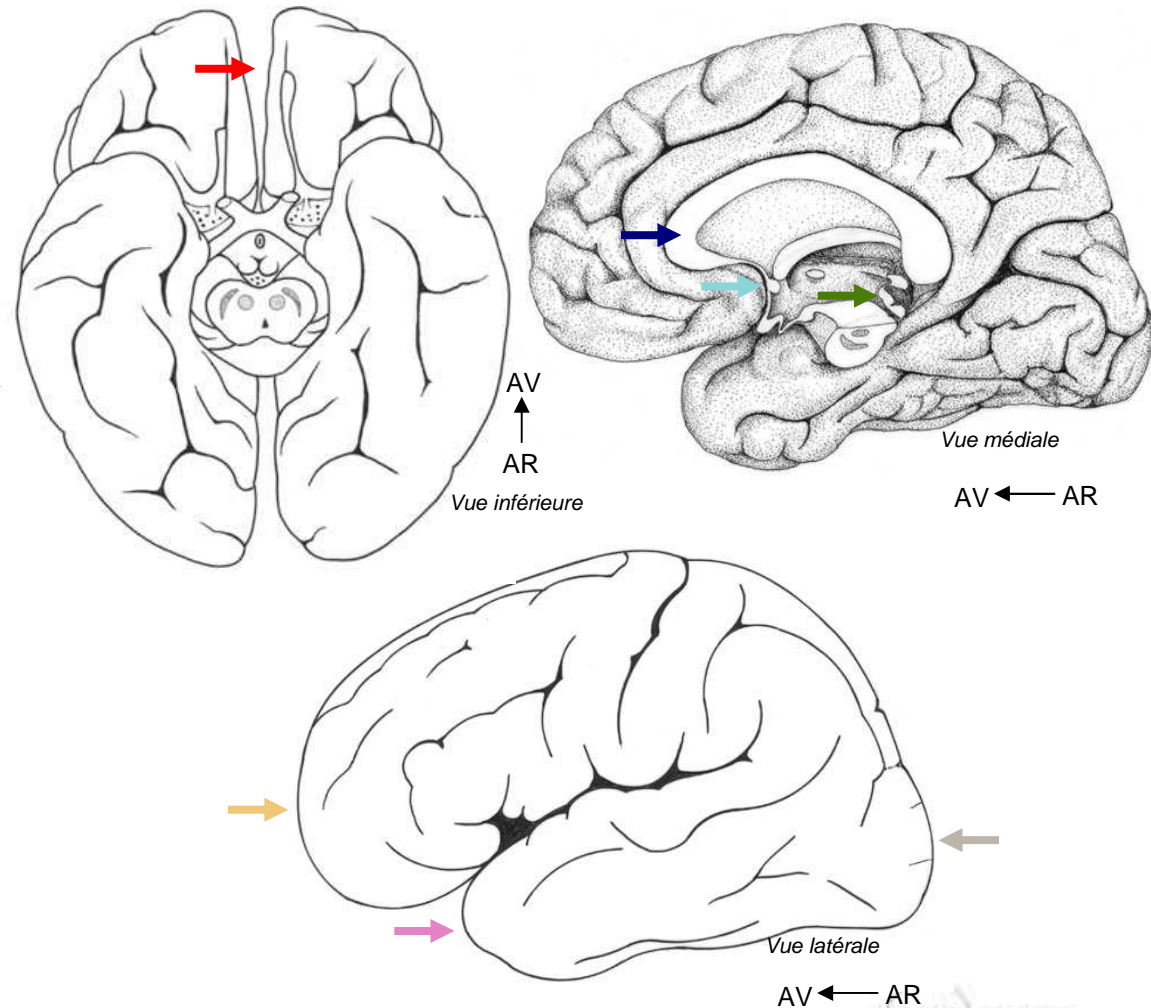
- Glie radiaire
 - Zone marginale
 - > périphérie
- Migration des neuroblastes



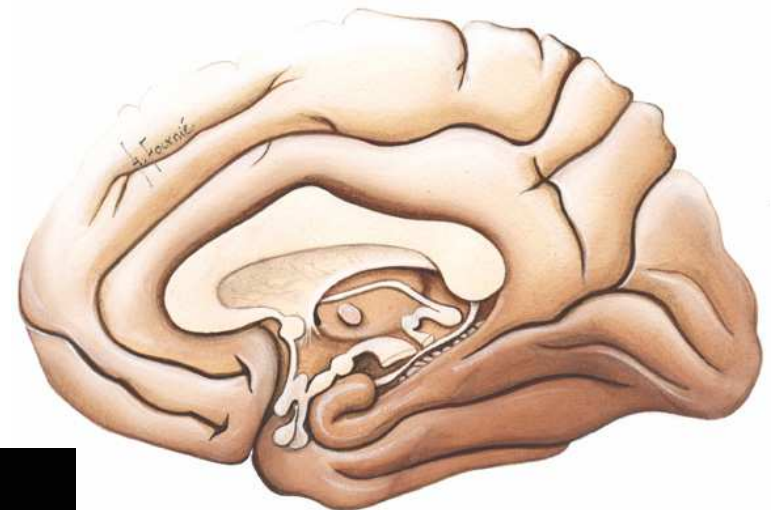
Glie radiaire – migration des neuroblastes

Anatomie : Faces et pôles

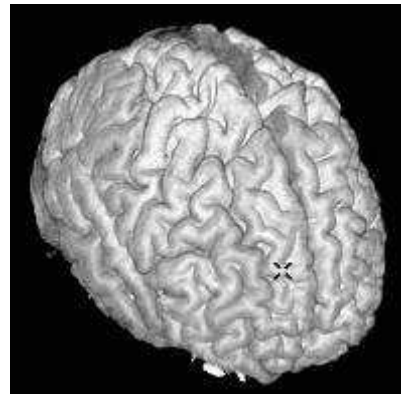- 2 hémisphères
- Fissure longitudinale →
- Commissures
 - Corps calleux →
 - Commissure antérieure →
 - Commissure postérieure →
- 3 Faces
 - Latérale
 - Inférieure
 - Face médiale
- 3 Pôles
 - Frontal →
 - Temporal →
 - Occipital →



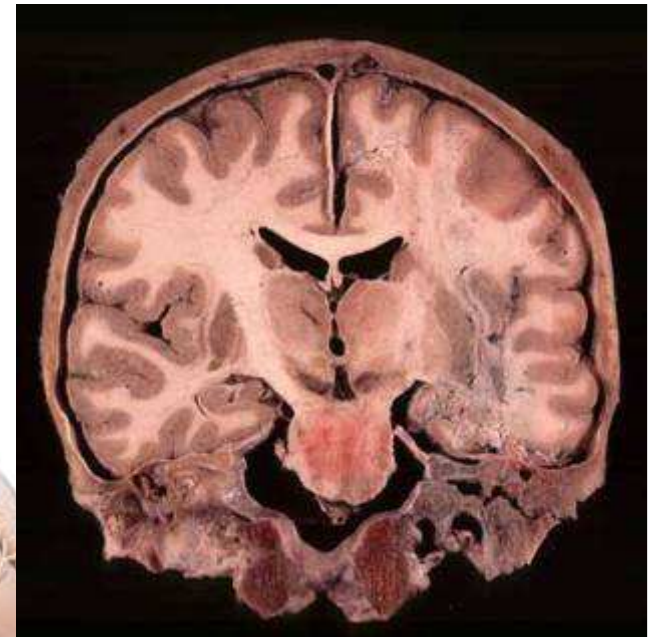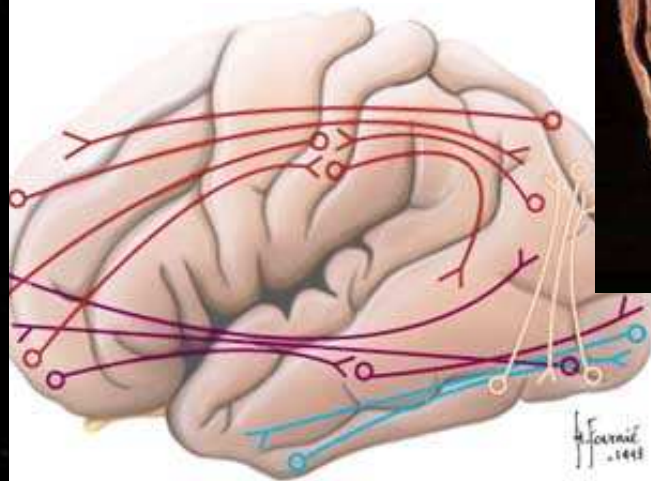
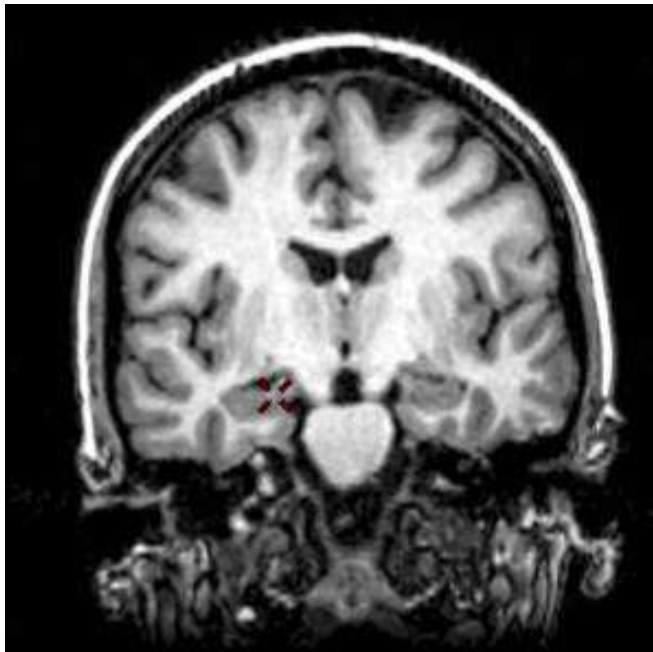
Hémisphères : sillons et lobes



- Cortex, SB et Nx

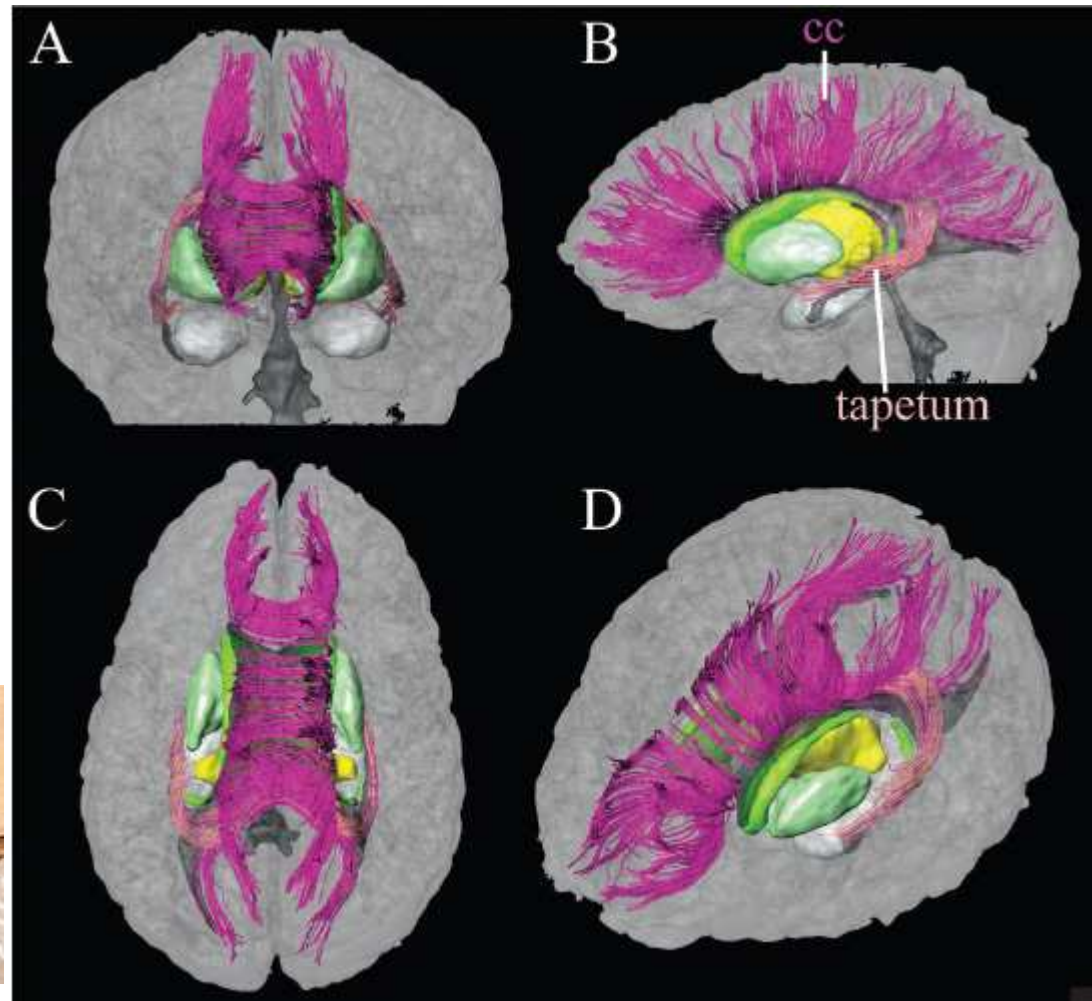
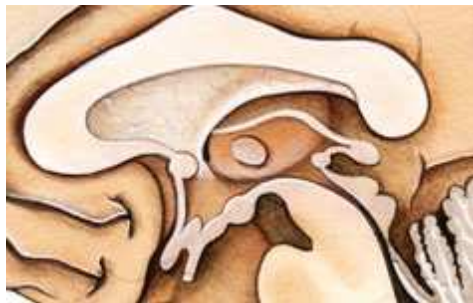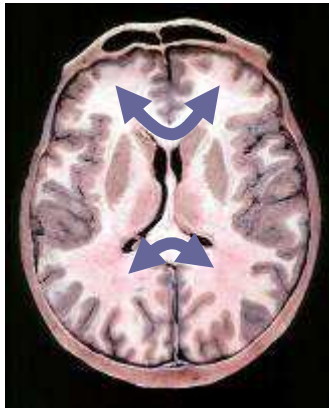


Substance blanche (SB) et Noyaux



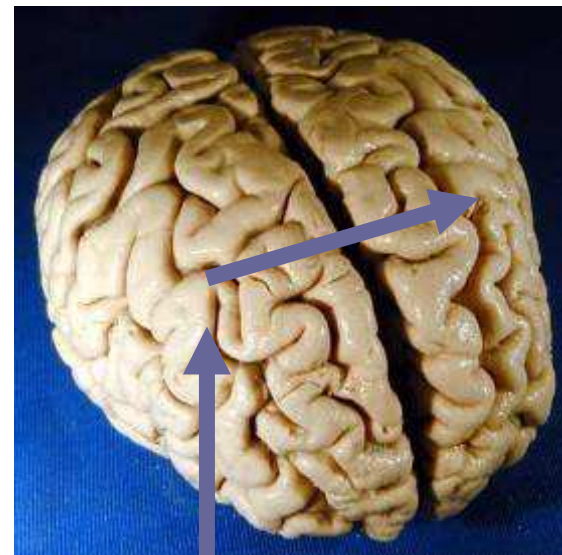
SB : Corps calleux

- Interhémisphérique
- Rostrum (bec)
- Genou : F
- Tronc : F, P
- Splenium : T, O
- Tapetum :
le long du VL
(entre paroi lat corne post
et radiation optique)

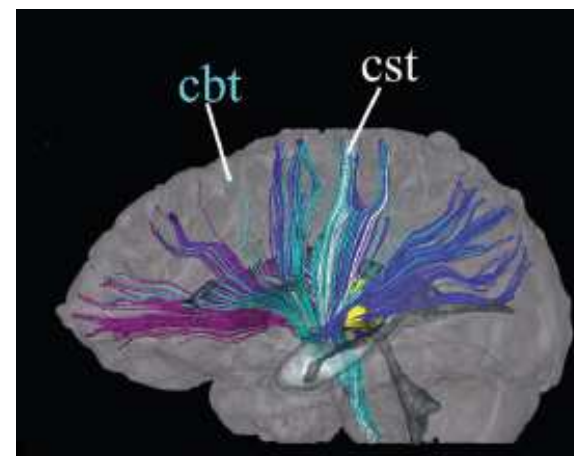
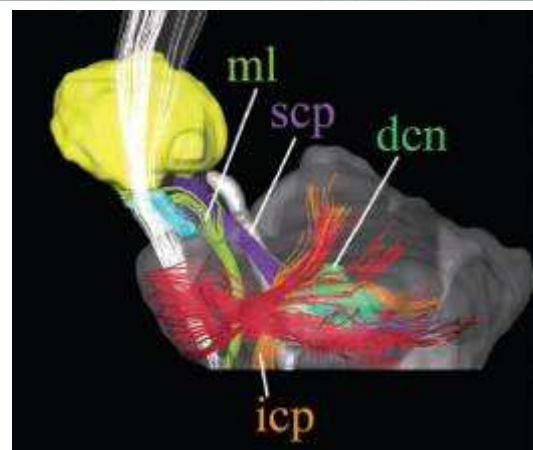
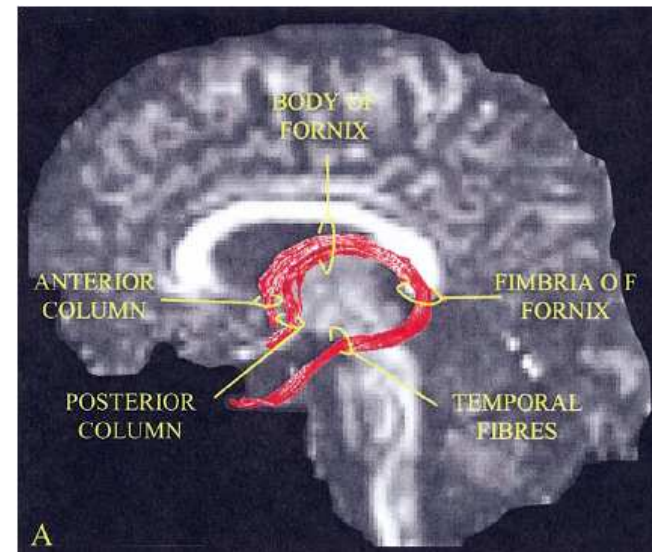
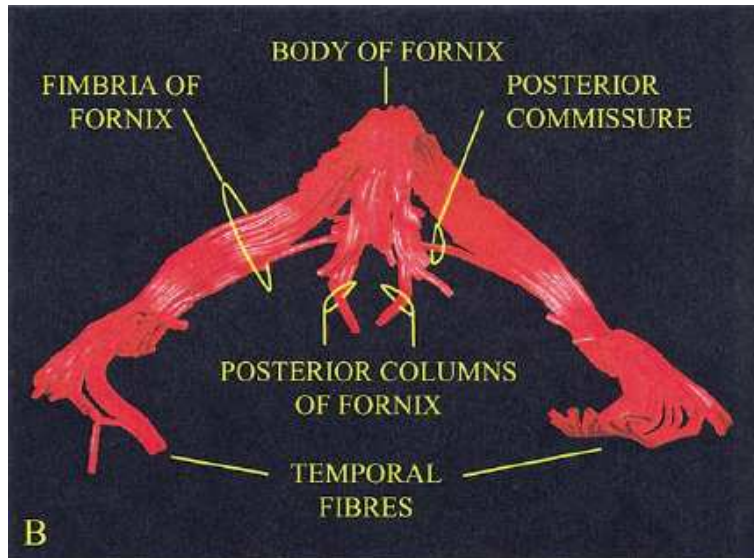


SB : Dysconnexion calleuse

- Anomie tactile main G



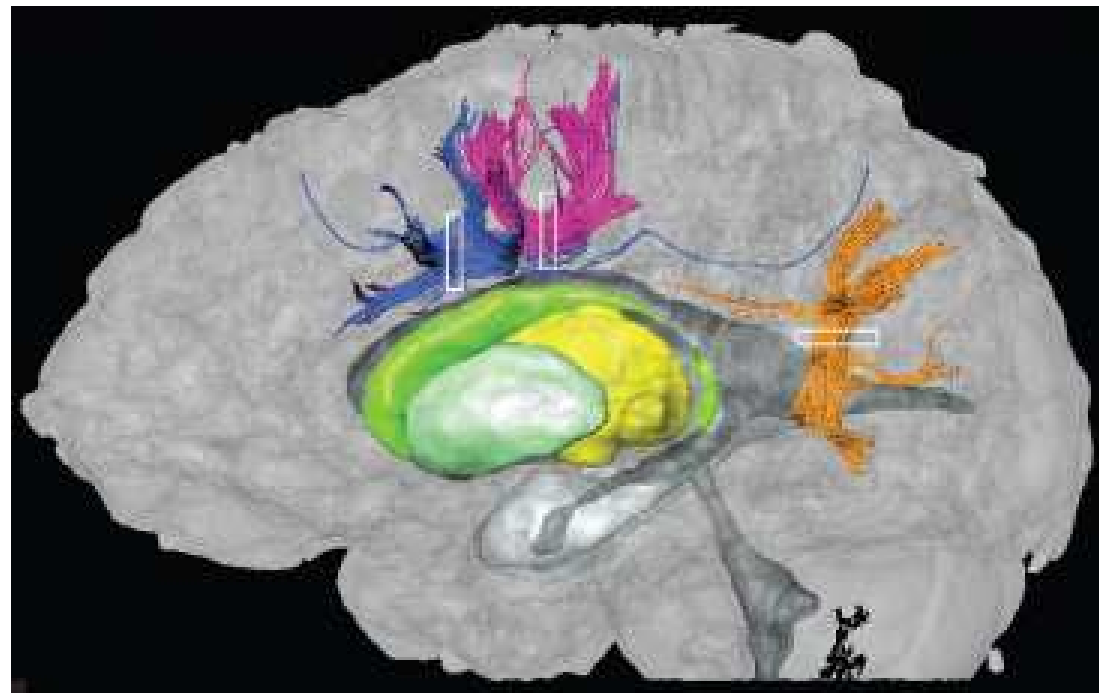
SB : fornix



SB : Fibres en U

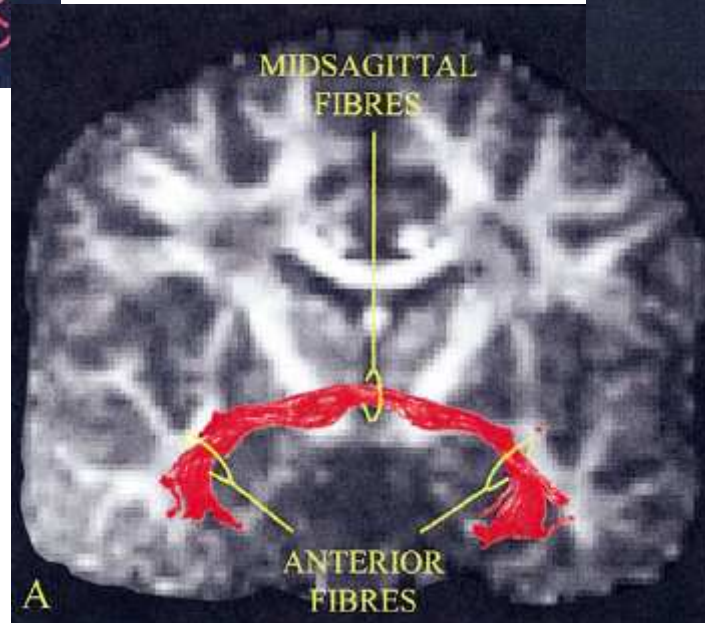
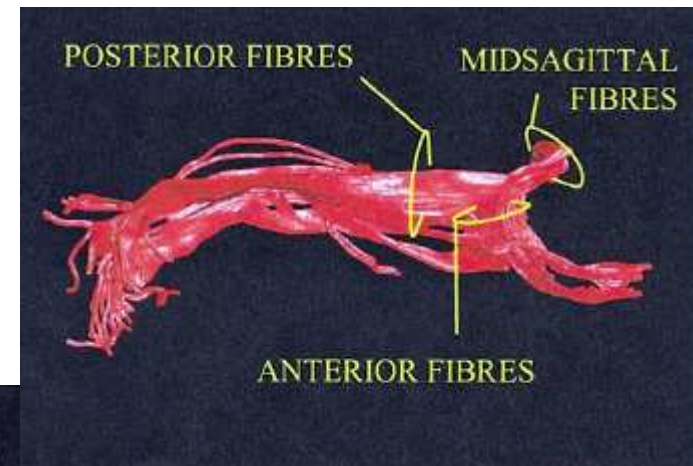
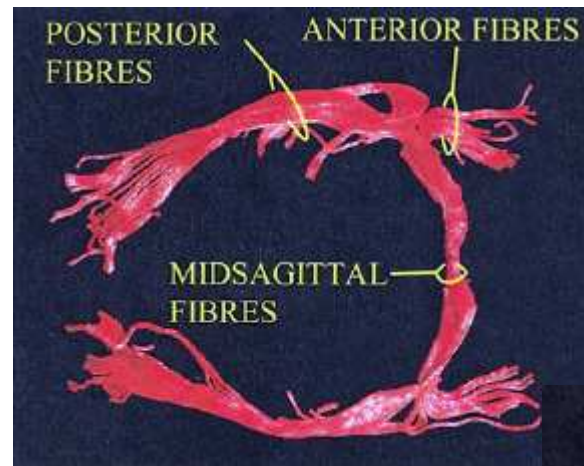
- Fibres arquées (en U)
- Gyri +/- adjacents

Setsu Wakana, Radiology 2004; 230:77-87

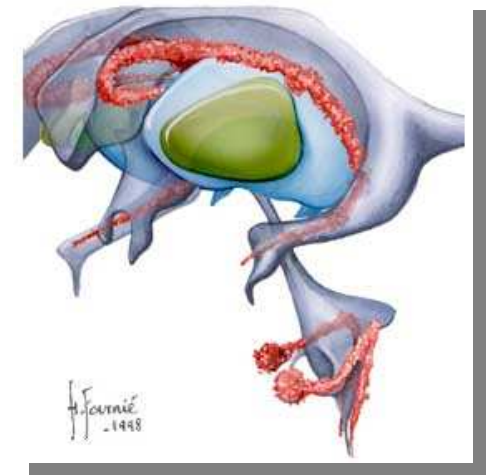
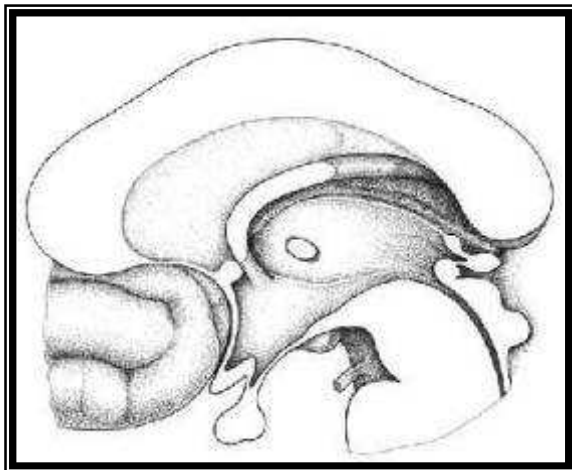
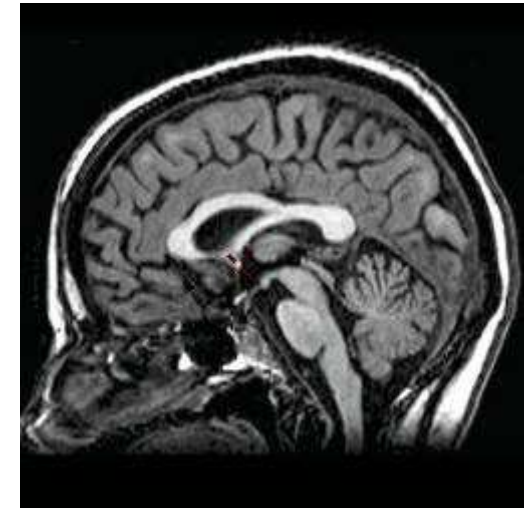
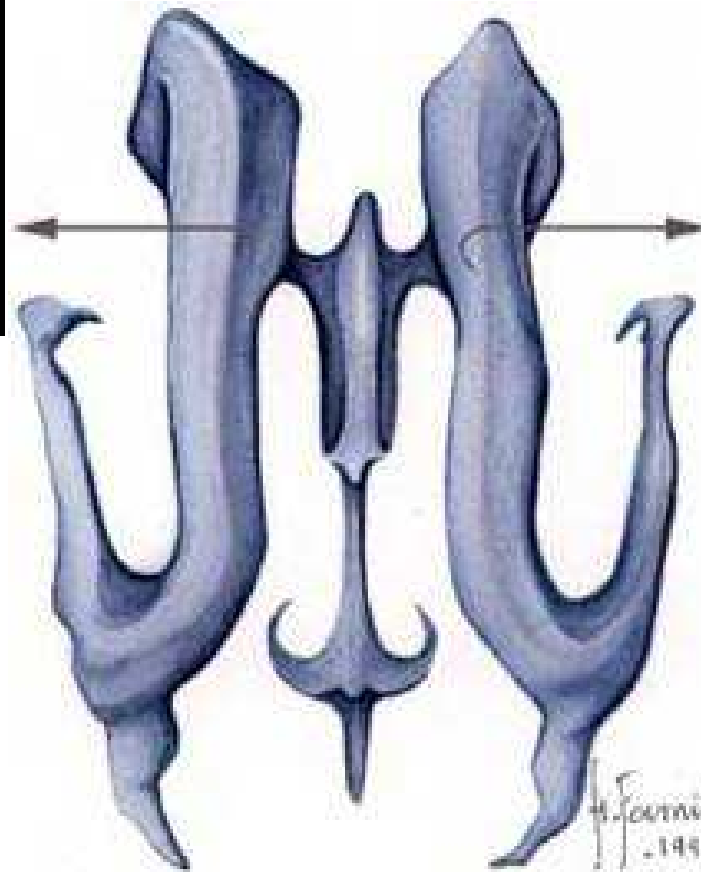
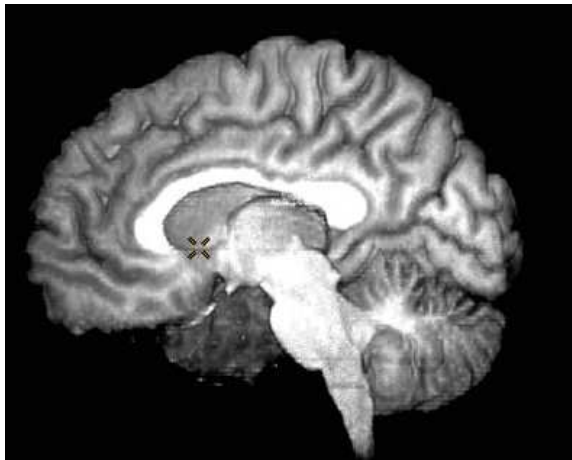


D. Hasboun 2007-2008

Commissure antérieure

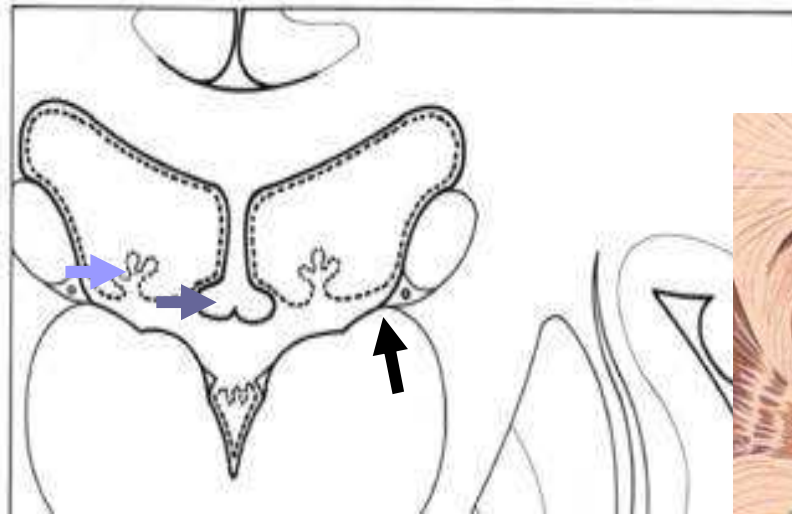


Ventricules

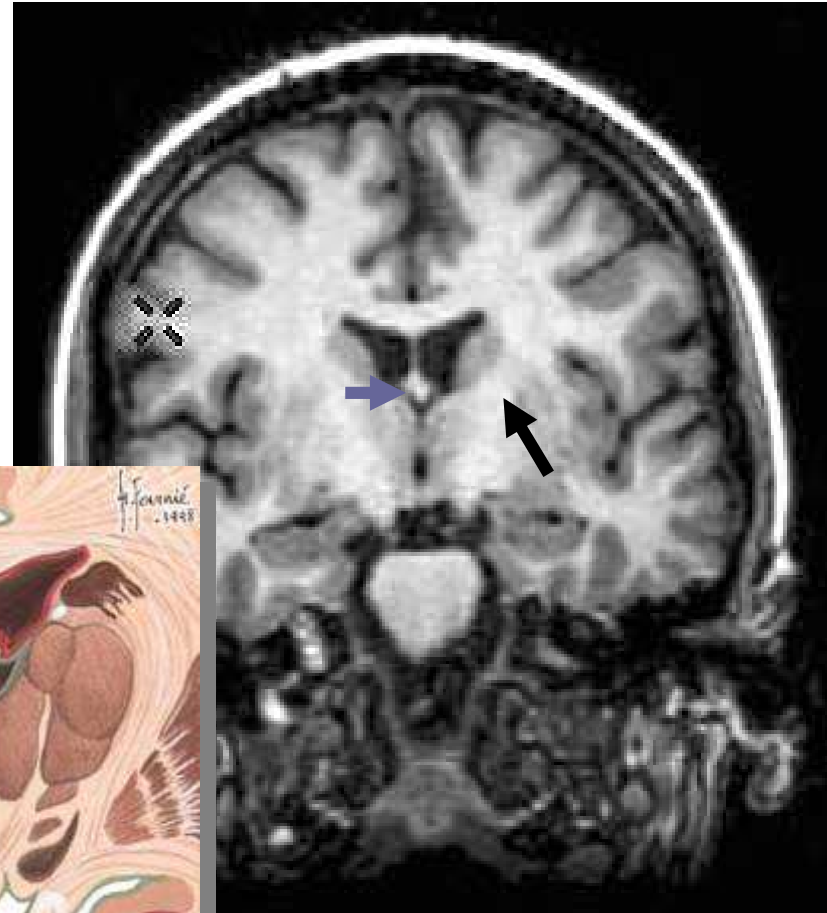
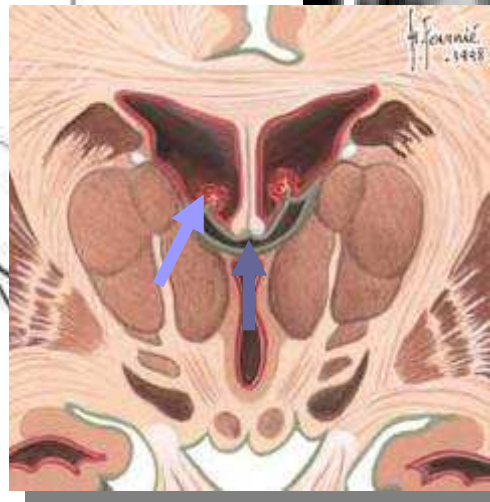

Ventricules

- Fornix →
- Plexus Choroïdes →
- Sillon thalamostrié →

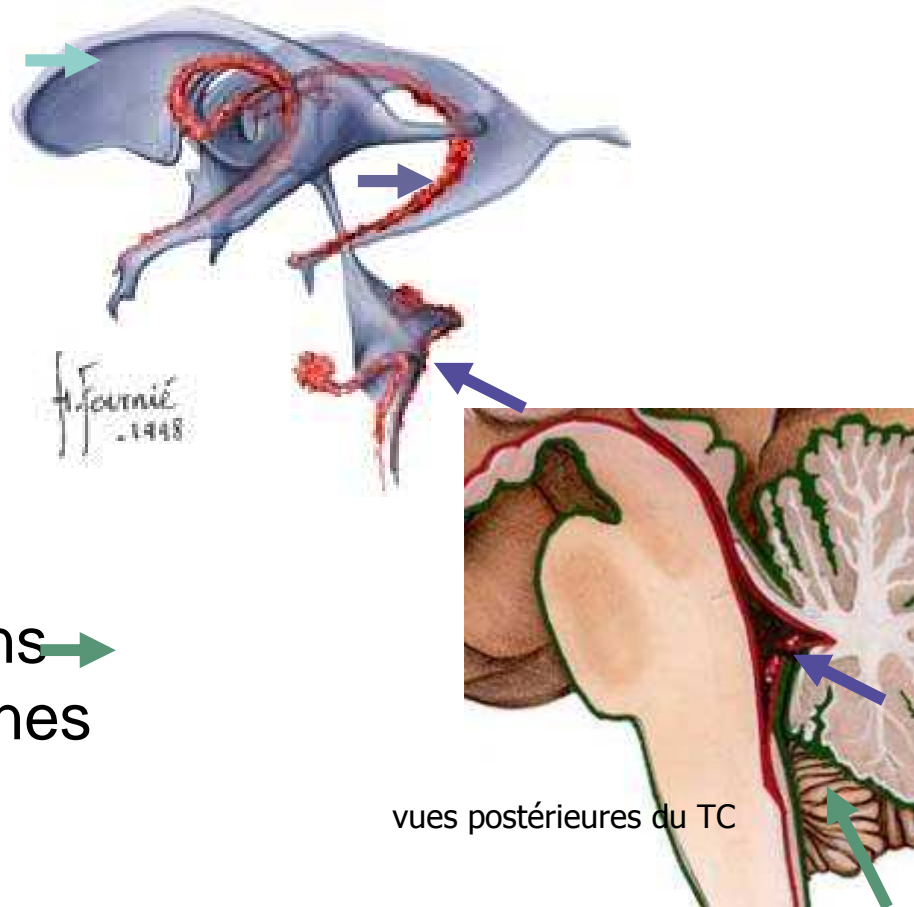


Coupes coronales



Dynamique du LCR

- Production : VL-V3-V4
 - cavités épendymaires →
 - plexus choroïdes →
- Communication :
ouverture médiane →
- Résorption
 - espaces sous-arachnoïdiens →
 - granulations arachnoïdiennes
 - Sinus veineux

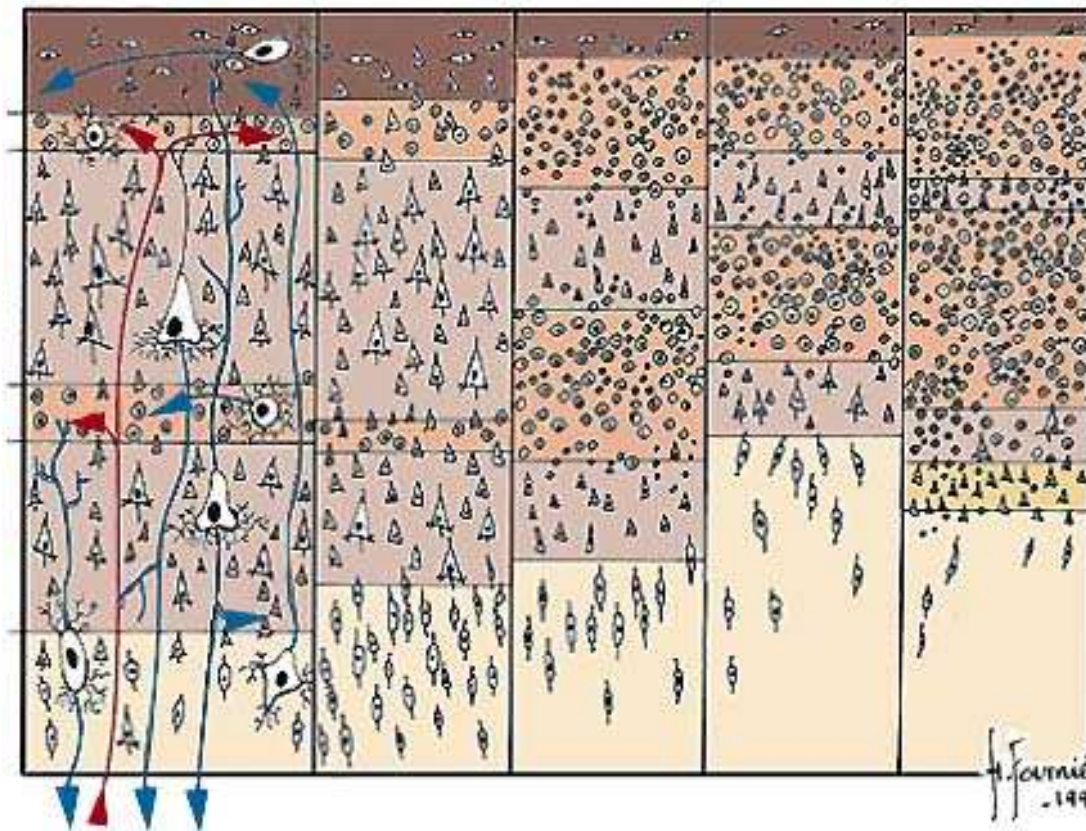


vues postérieures du TC

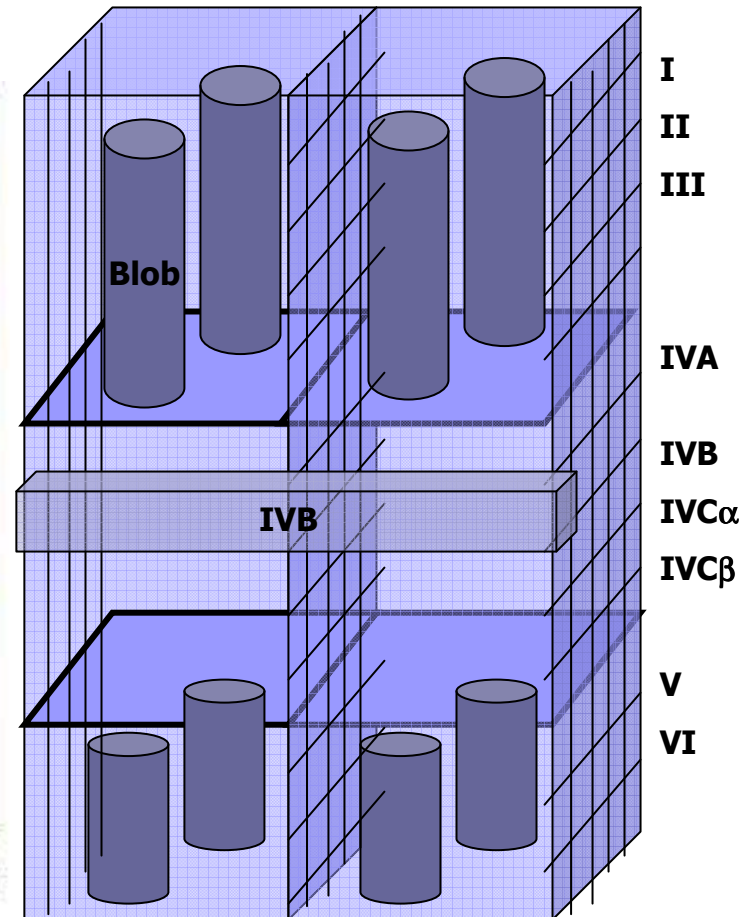


Anatomie
Fonctionnelle

Cortex : organisation fonctionnelle

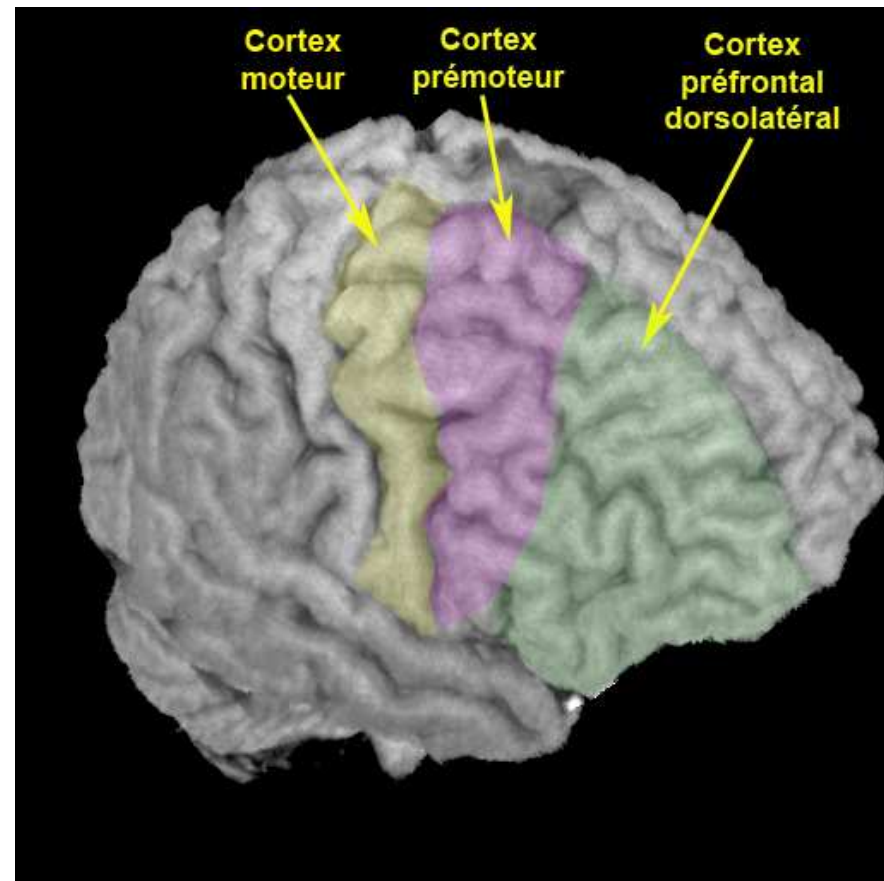
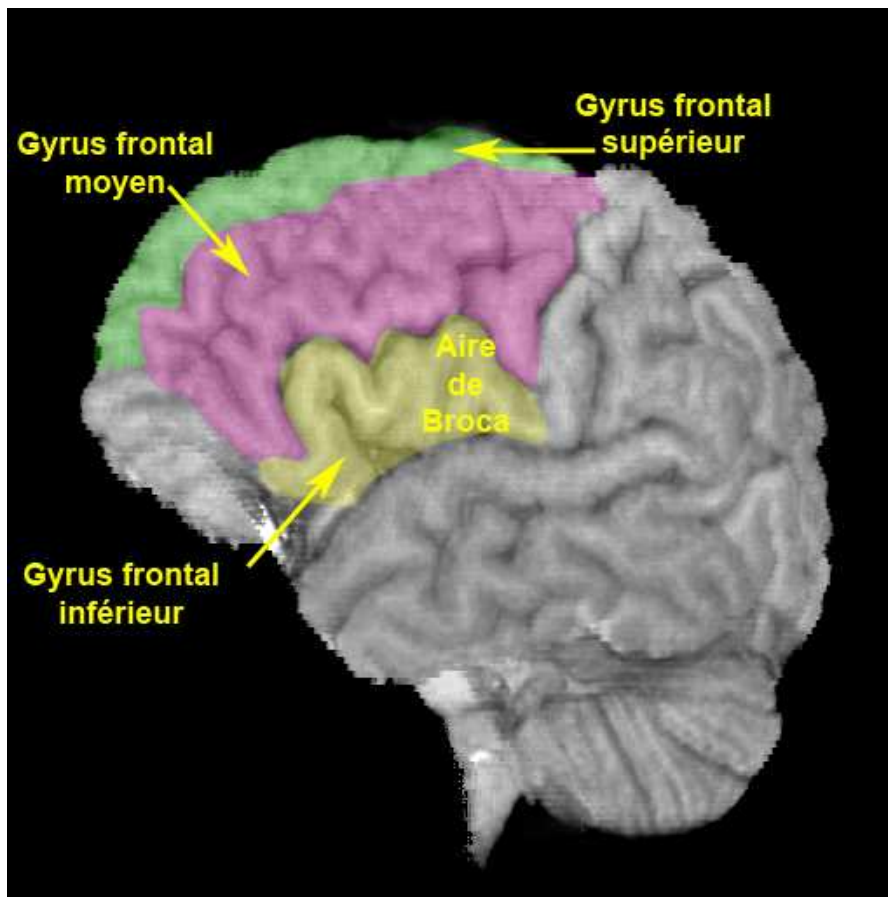


Différents types de cortex : histologie



2 colonnes du cortex visuel

Lobe frontal



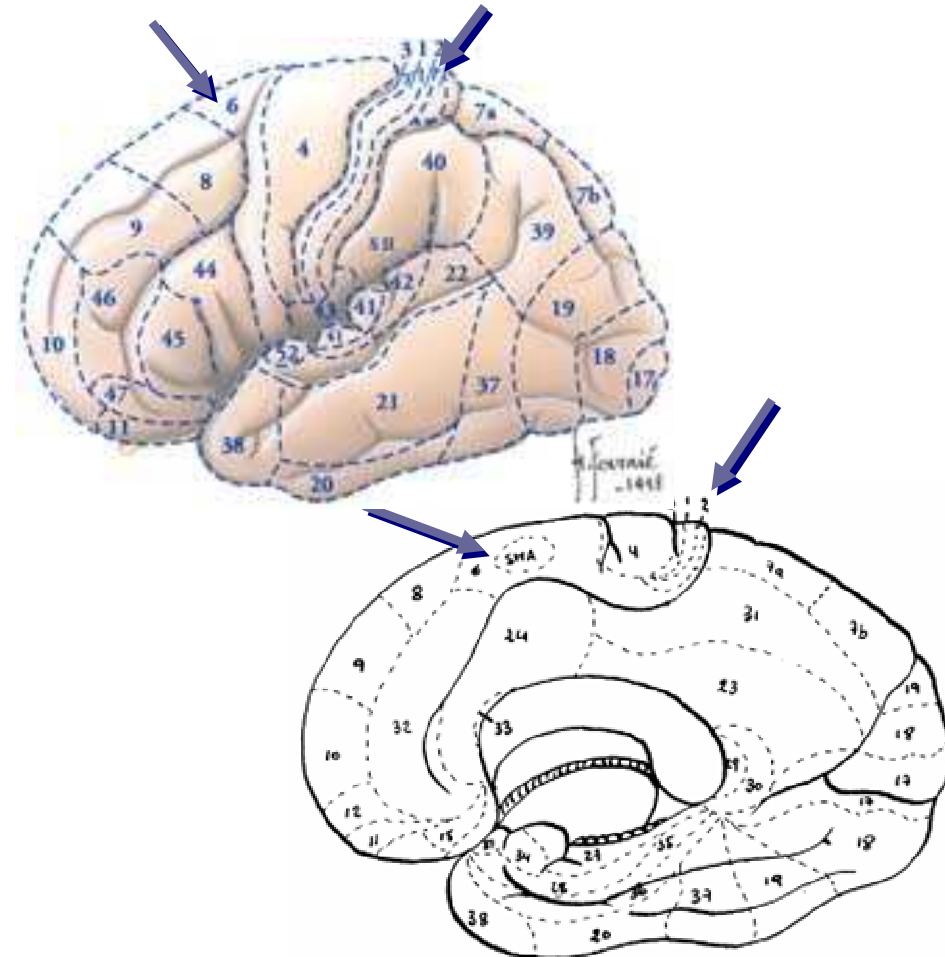
Motricité : Région centrale +

- **Prémotrice**

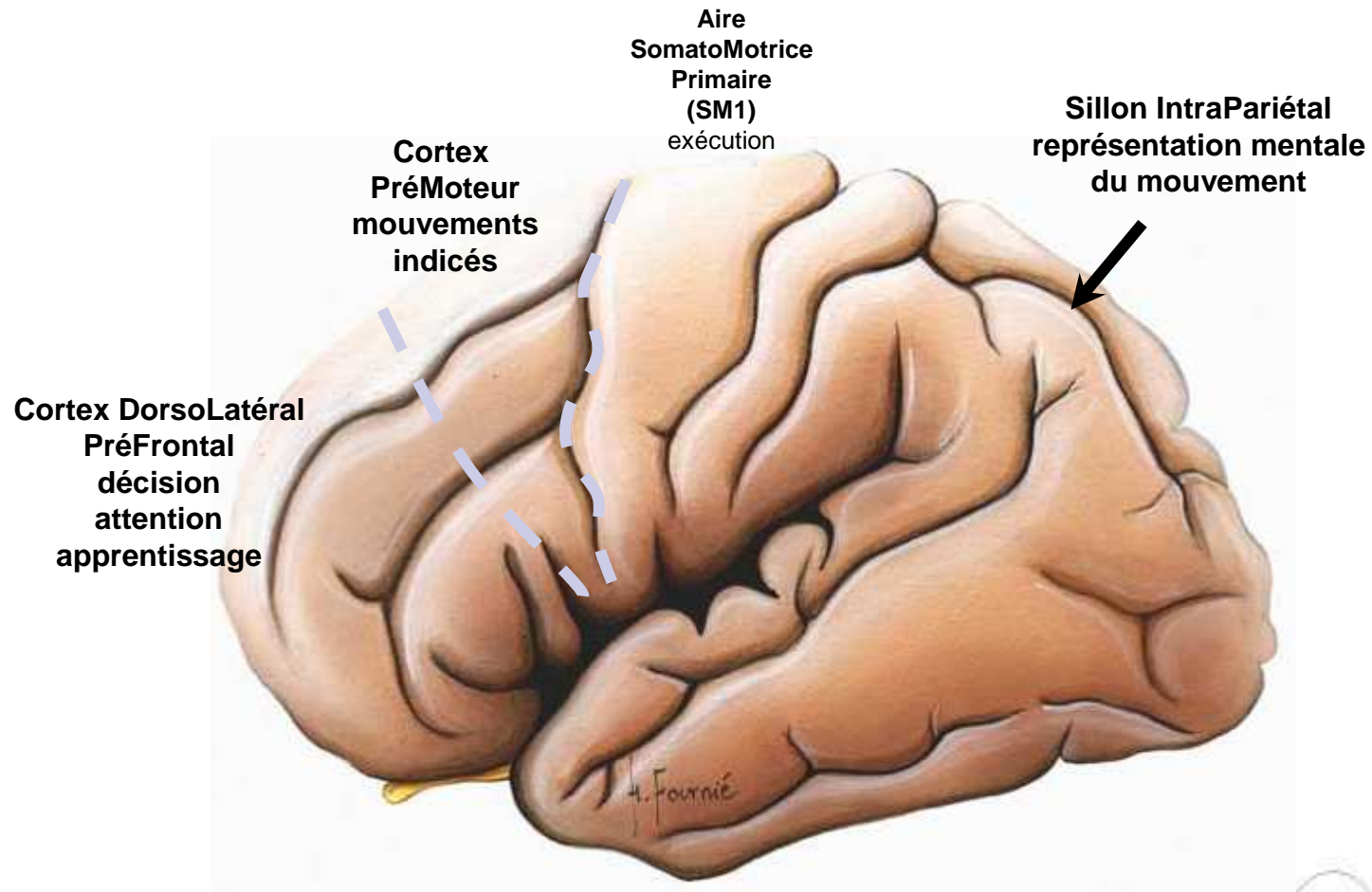
- 6, SMA

- **Pariétal**

- 3, 1, 2



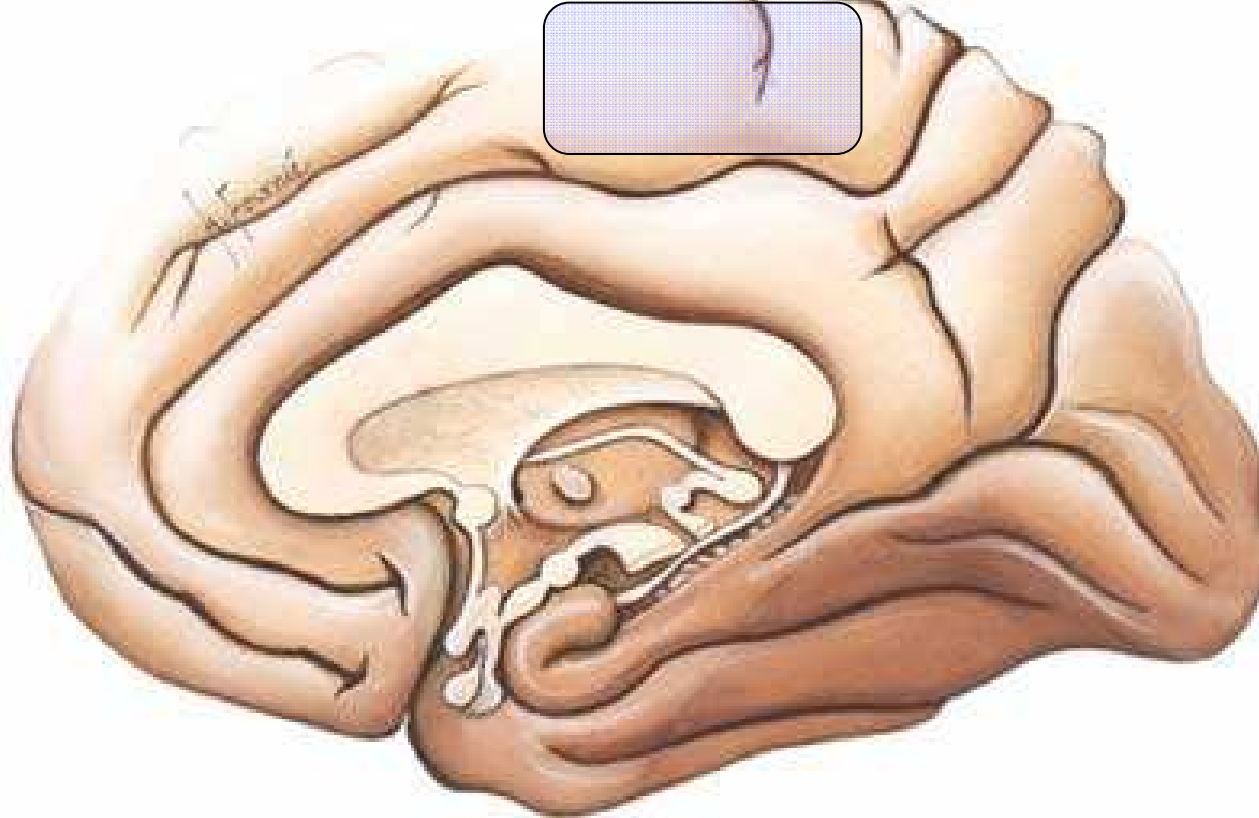
Motricité



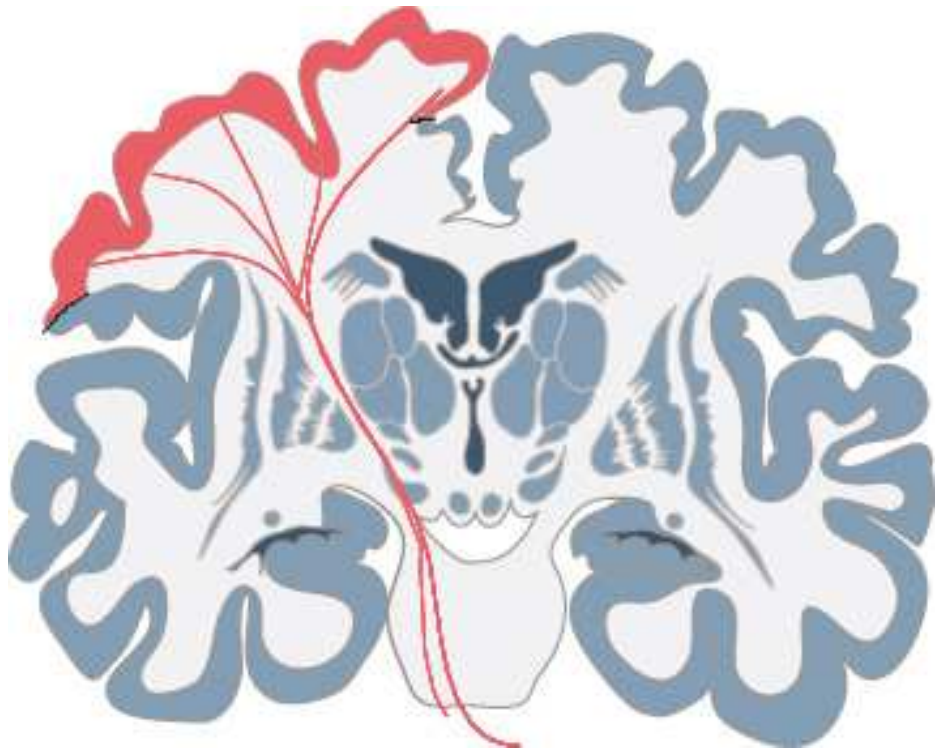Motricité

Aire Motrice Supplémentaire
antérieure
Sélection, préparation, séquence

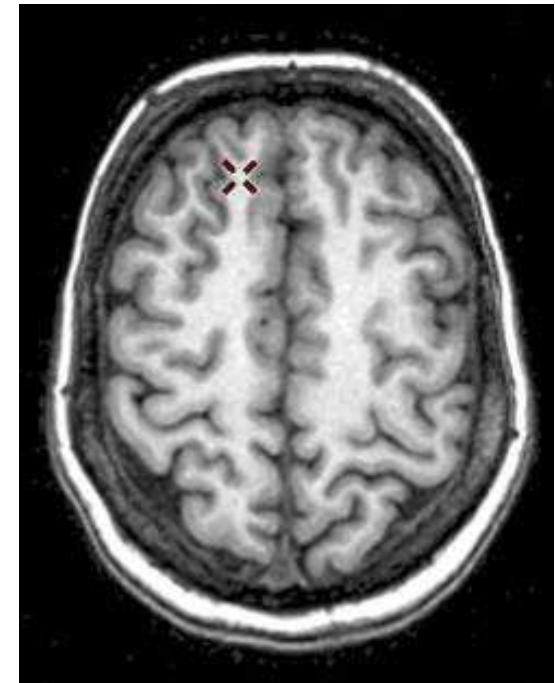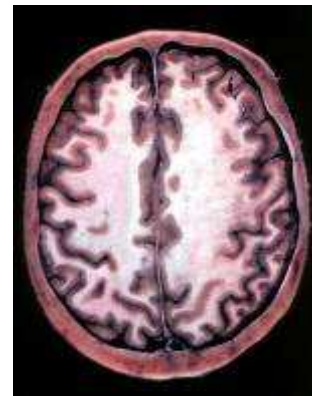Aire Motrice Supplémentaire
postérieure
exécution, initiation



Trajet : *corona radiata*

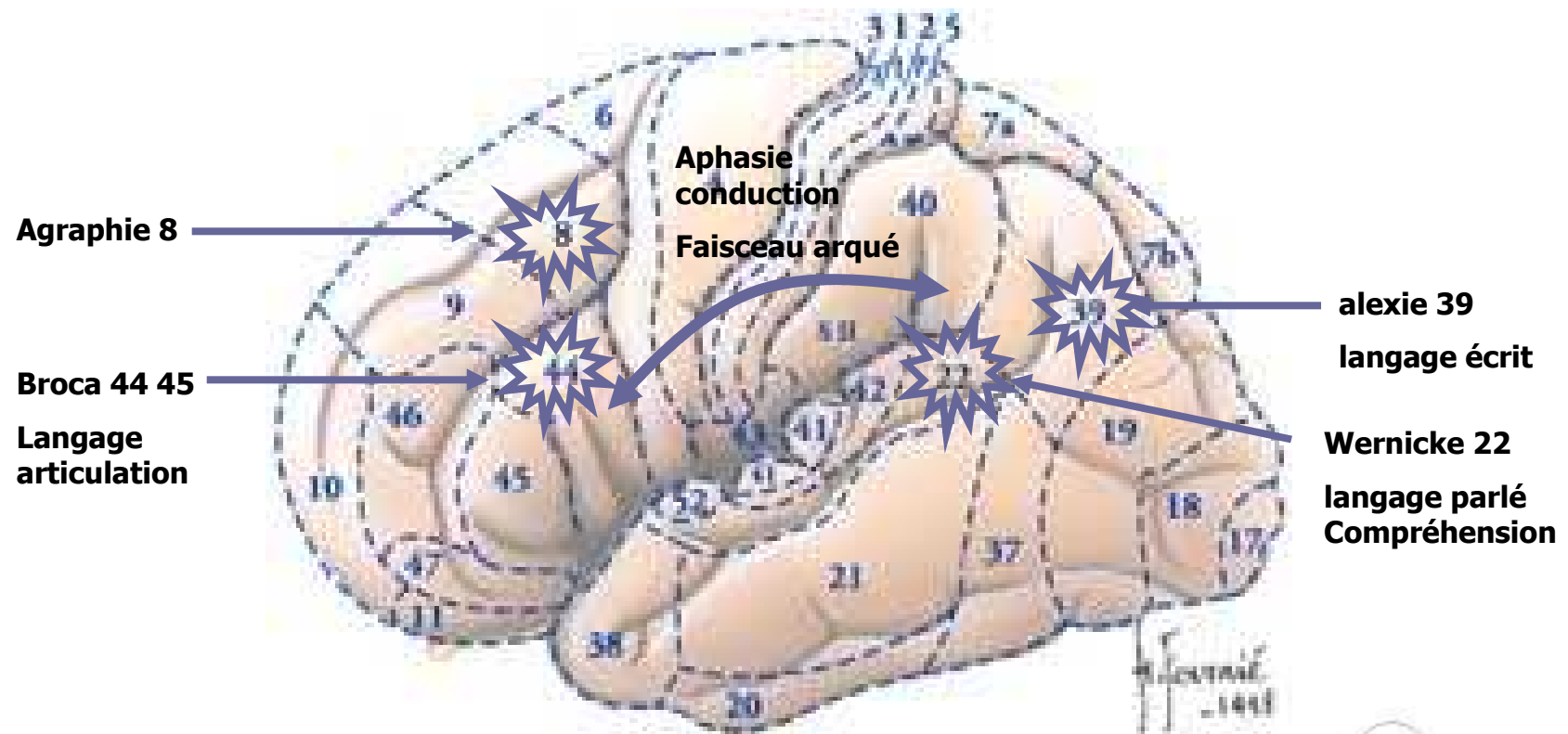


Coupe coronale



Coupes axiales Anatomique – IRM T1

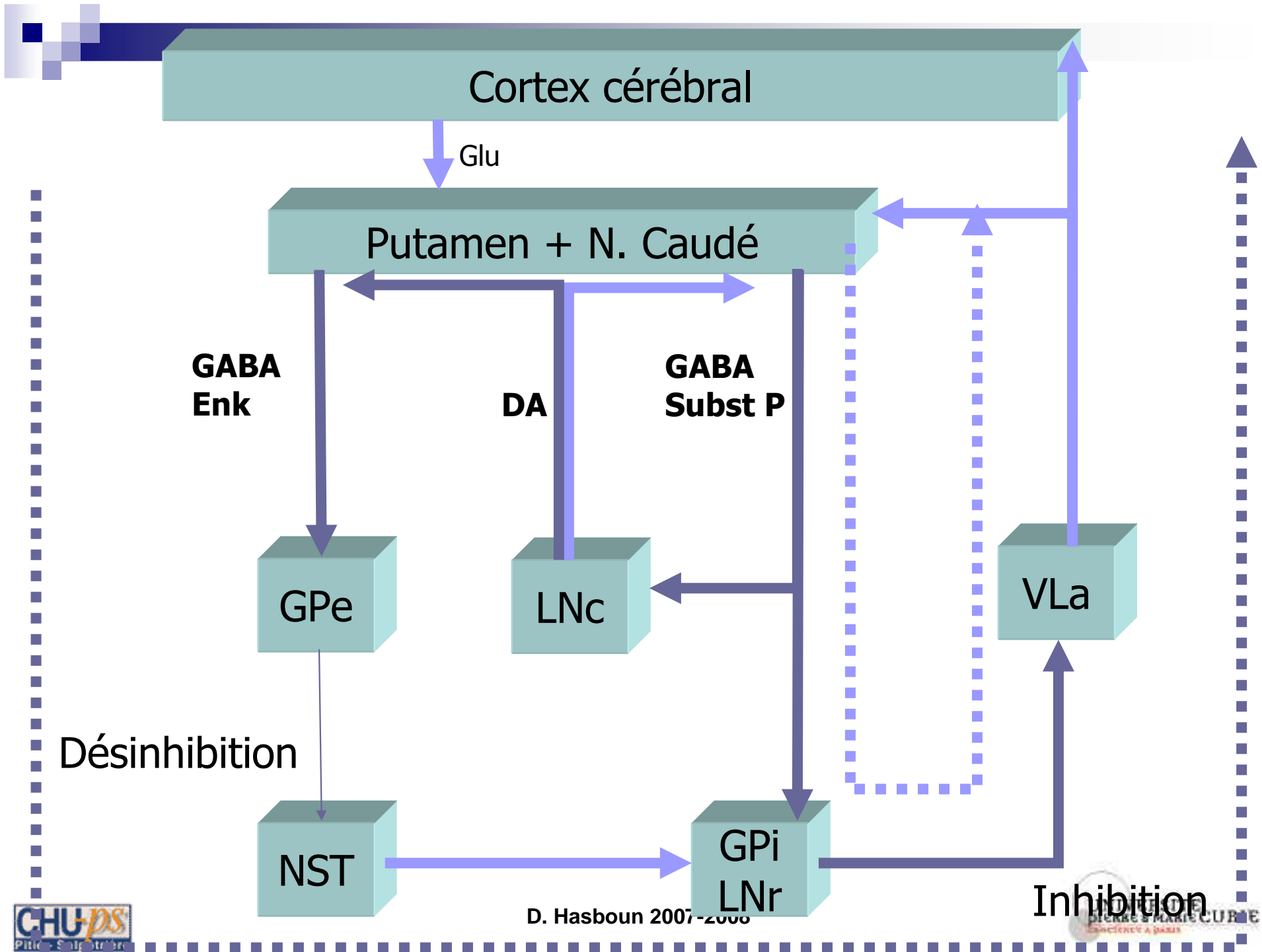
Langage



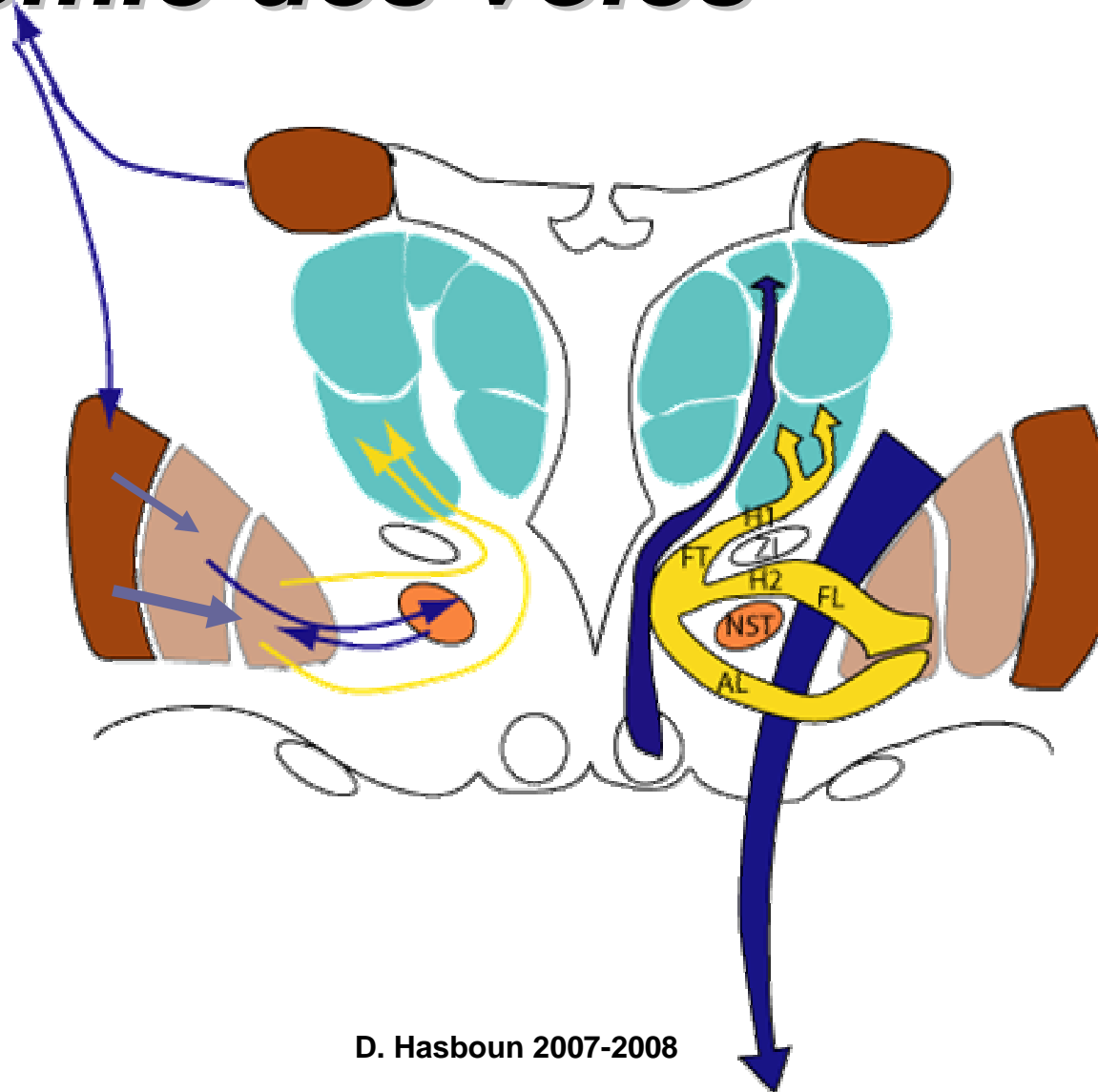
Aphasies

■ Pour en savoir plus....

	Broca	Wernicke	Conduction	Trans-corticale motrice	Trans-corticale sensorielle
Langage spontané	Non fluent	Fluent	Fluent	Non fluent	Fluent
Dénomination	- à +/-	-	+/-	-	-
Compréhension	+ à +/-	-	+	+	-
Répétition	-	-	-	+	+
Lecture	-	-	+	+	-
Ecriture	-	-	-	-	-
Lésion	<u>Aires 44-45 G</u>	<u>Aire 22 G</u>	<u>Faisceau arqué G</u> <u>Opercule pariétal</u>	<u>Lobe préfrontal G</u>	<u>Partie inférieure du lobe temporal G</u>

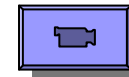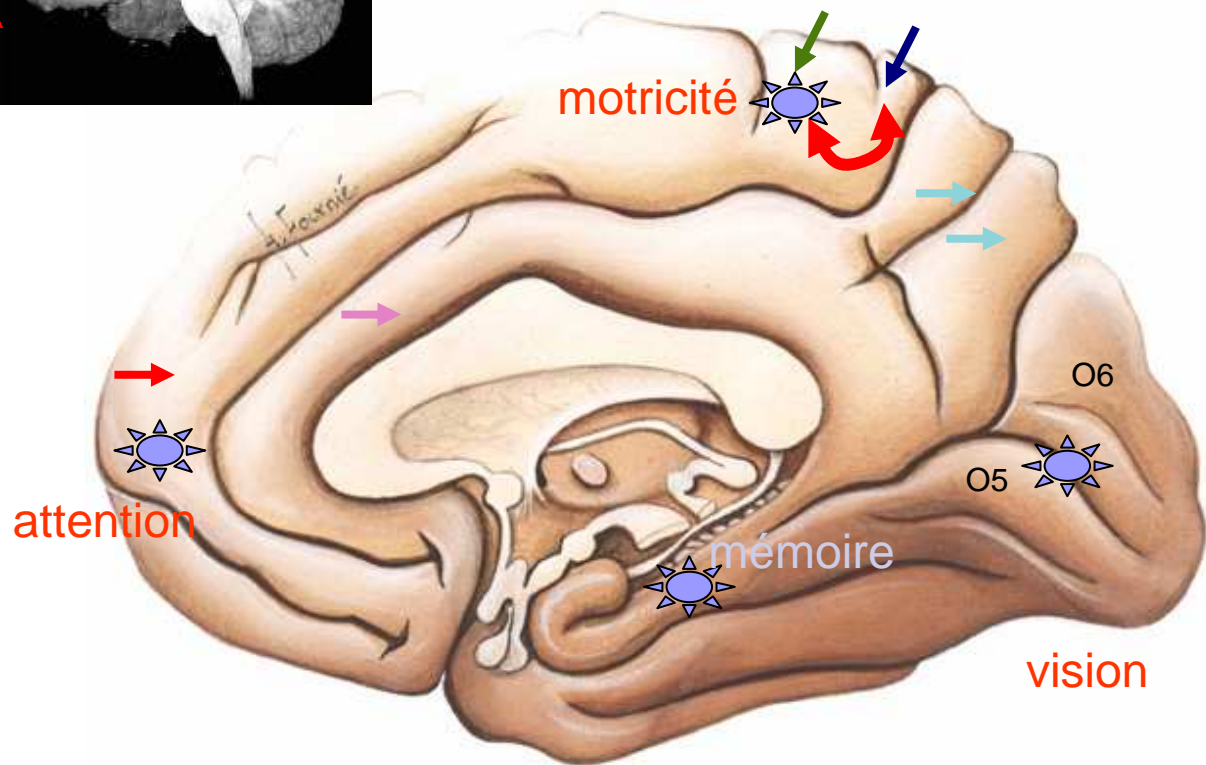

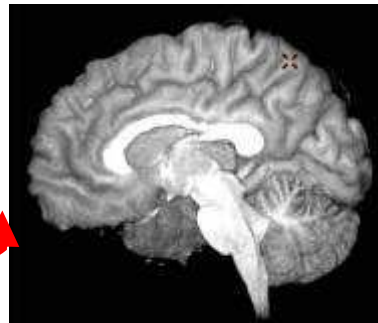
Anatomie des voies

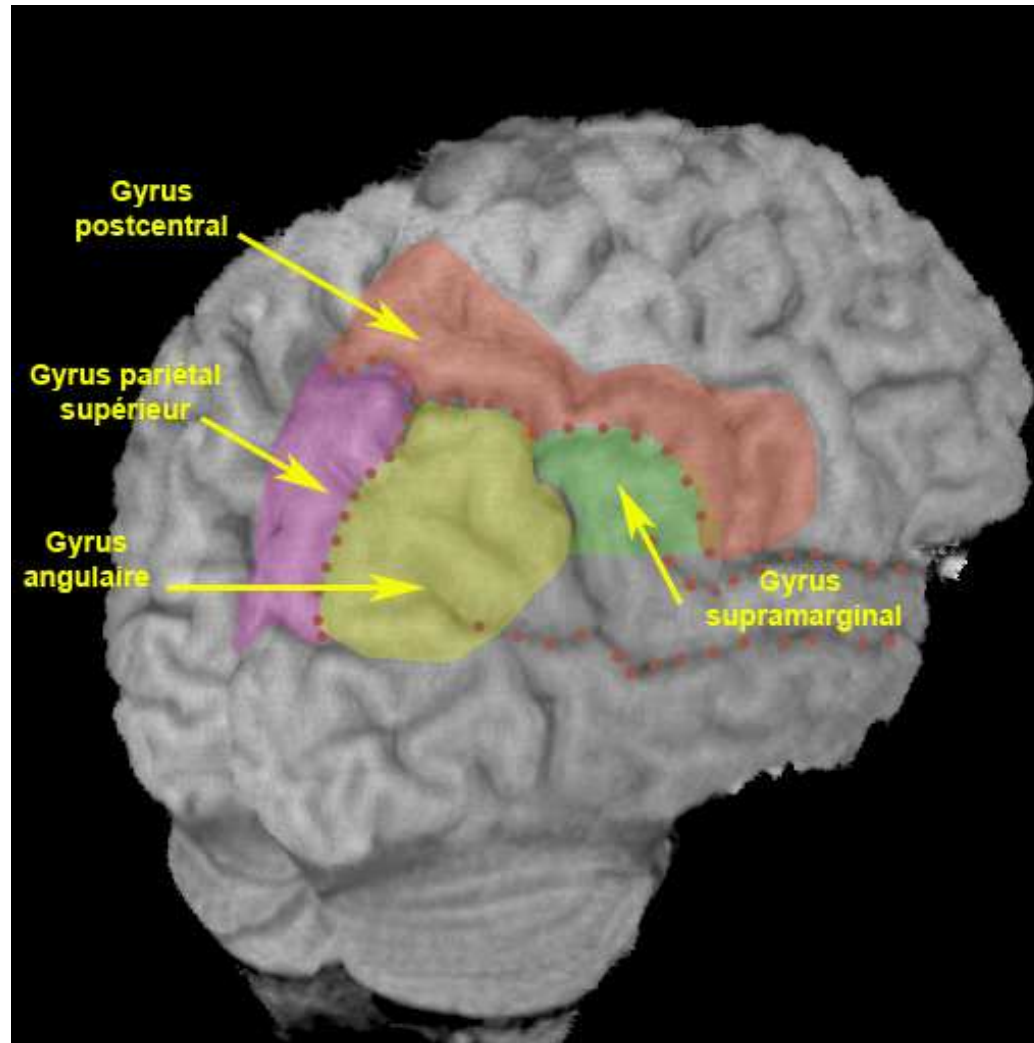


Télencéphale

- Frontal
 - F1 →
 - Gyrus précentral →
 - Lobule paracentral ↻
- Pariétal
 - Gyrus postcentral →
 - Précunéus →
- Lobe limbique
 - Gyrus cingulaire →
- Occipital
 - Cunéus O6
 - Gyrus lingual : O5
 - Gyrus fusiforme : O4
 - O3
- Temporal
 - T5, T4, T3

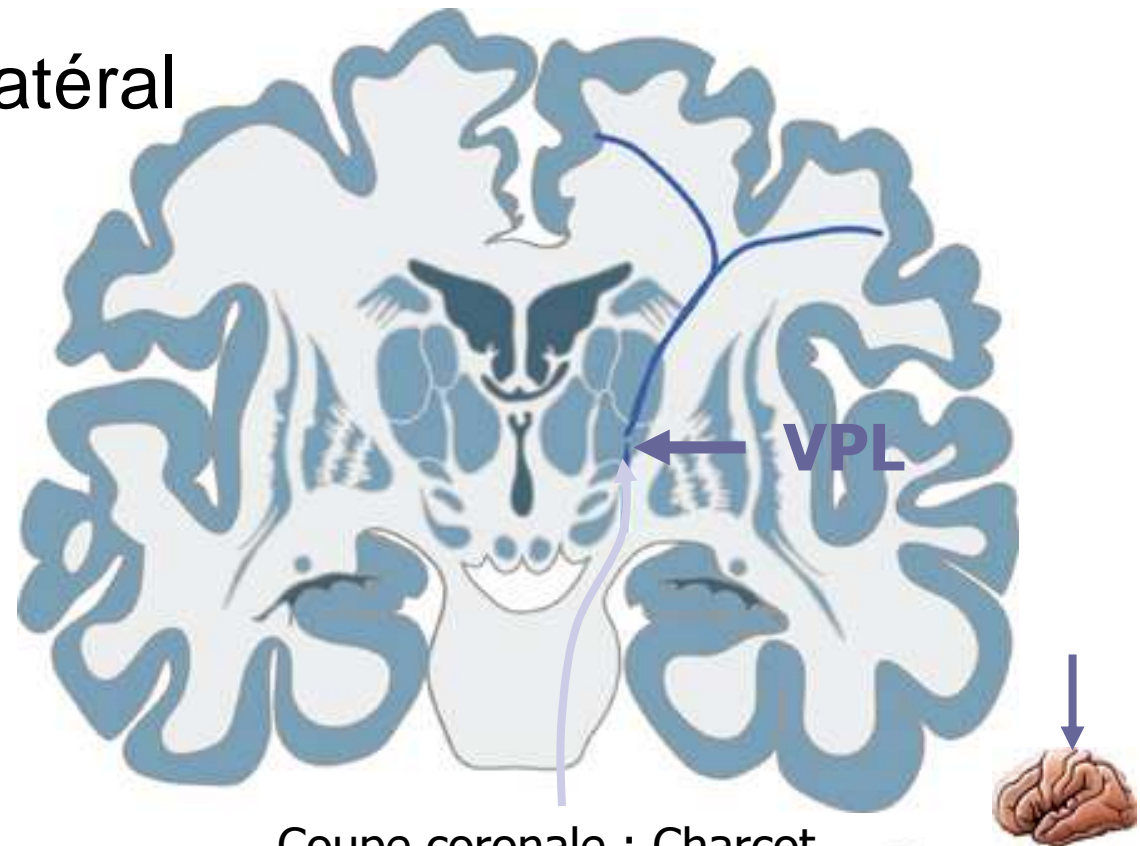


Pariétal : Praxies



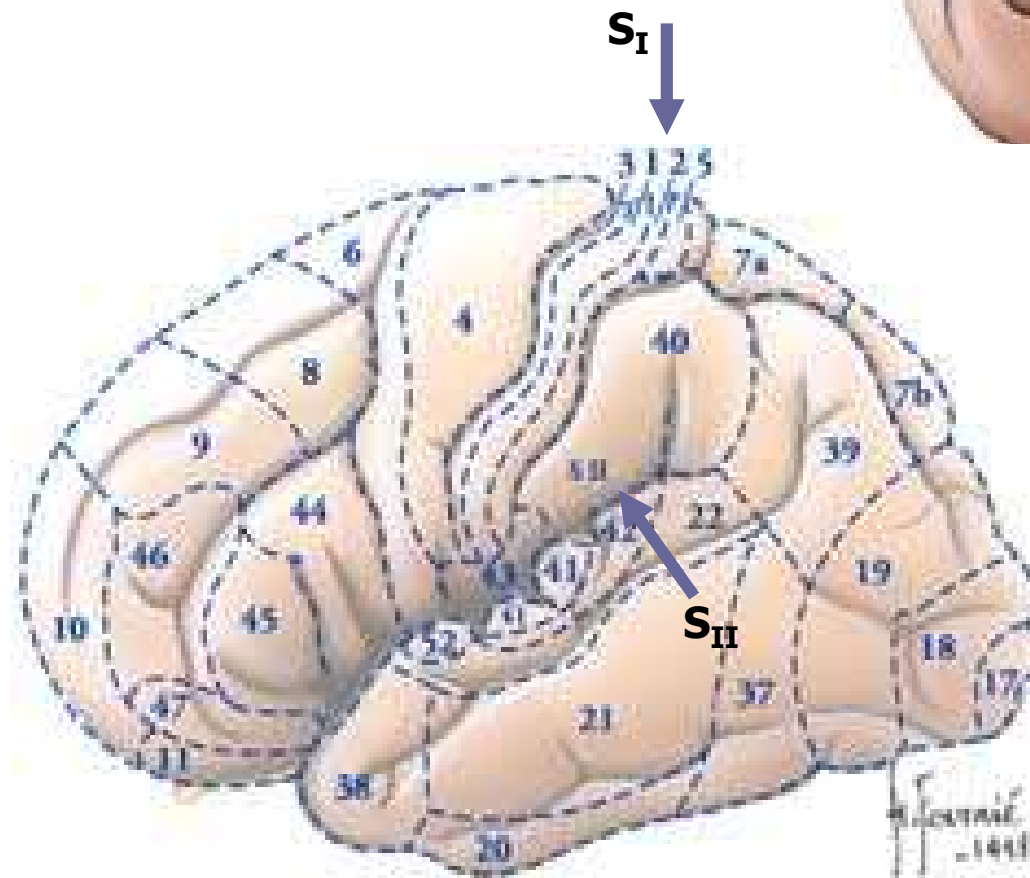
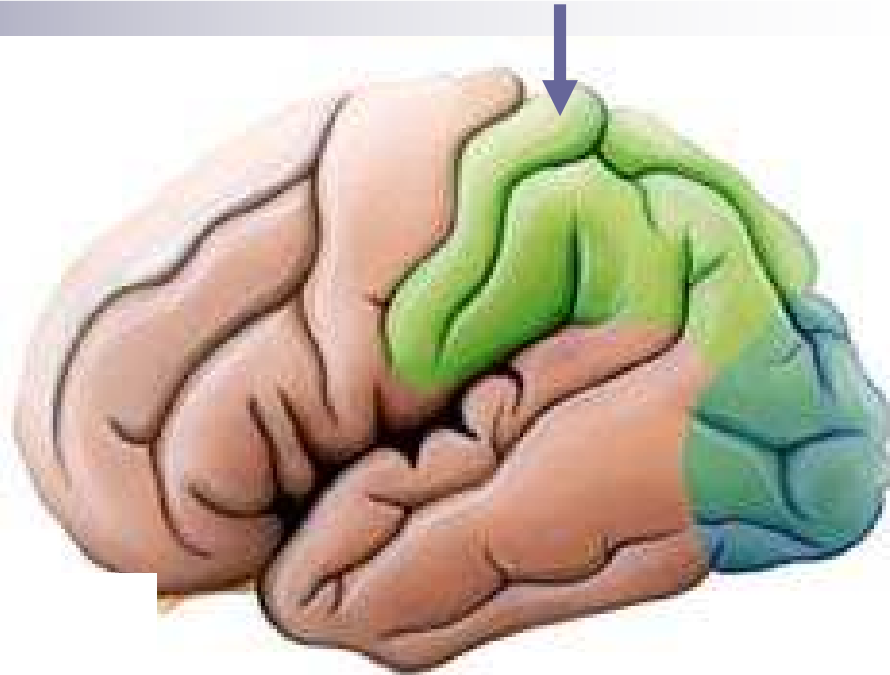
sensibilités

- Nx Ventral Postérolatéral
- Somatotopie
 - Dh -> Dd
 - MI -> MS
- Interaction avec ST



Coupe coronale : Charcot

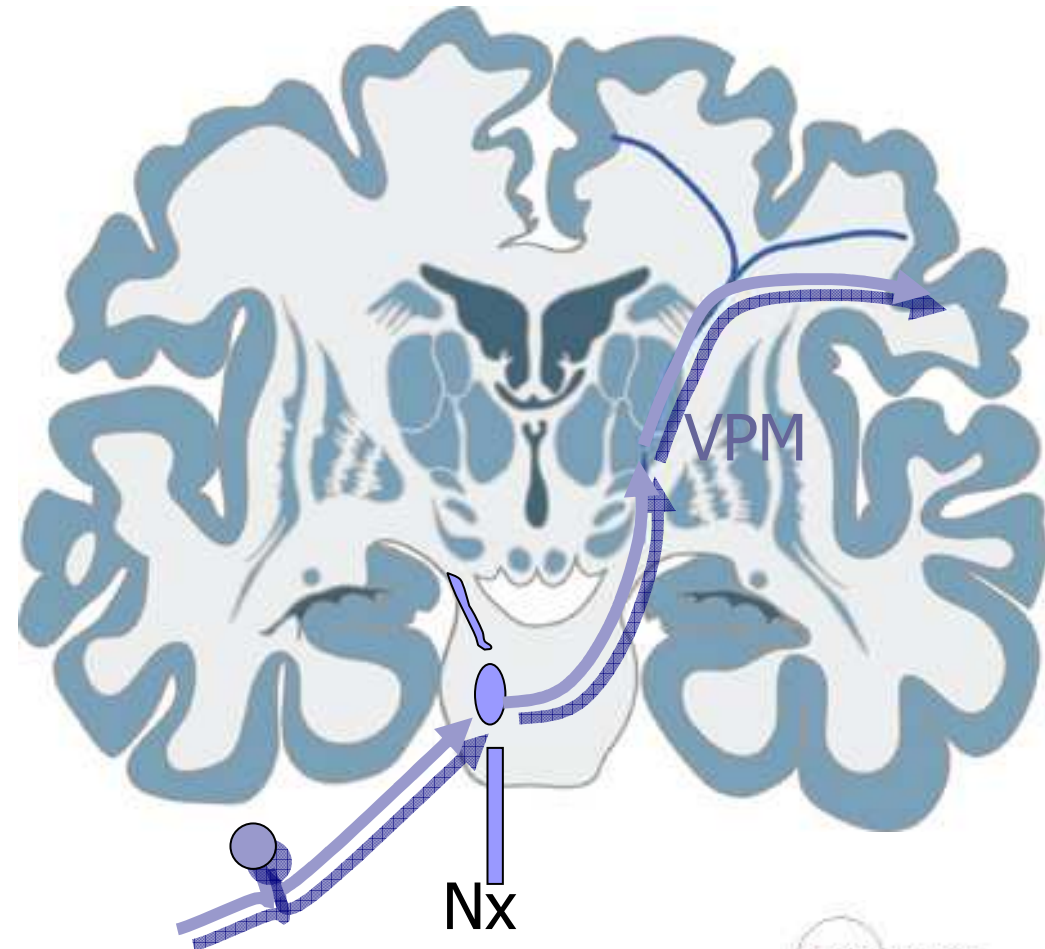
Cortex S_I S_{II}



- Gyrus postcentral
- Aires 3, 1, 2
- Somatotopies
- Face latérale : ACM
- Face médiale : ACA
- Via le bras postérieur de la Capsule Interne
- Organisation en colonnes

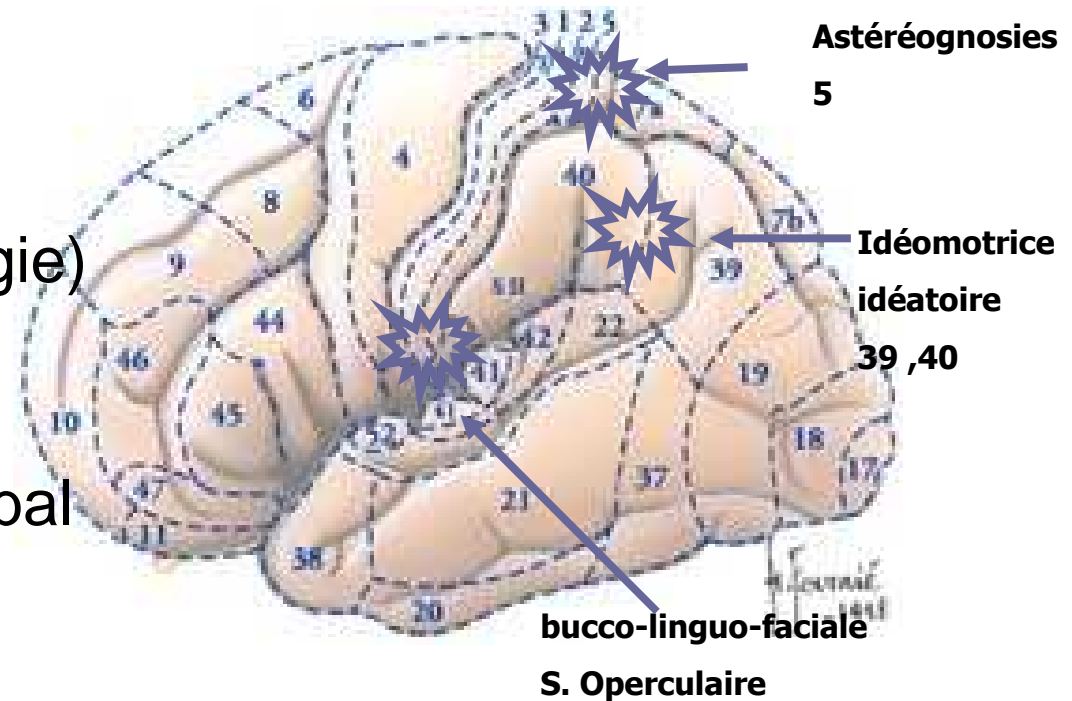
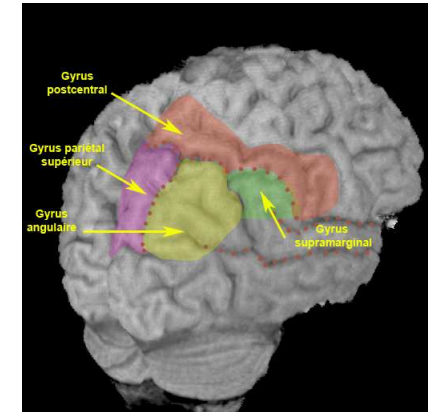
Sensibilité de la face

- Fx quintothalamique
 - Nx V -> VPM
- Relais thalamique
 - VPM
- Gyrus postcentral opercule Rolandique



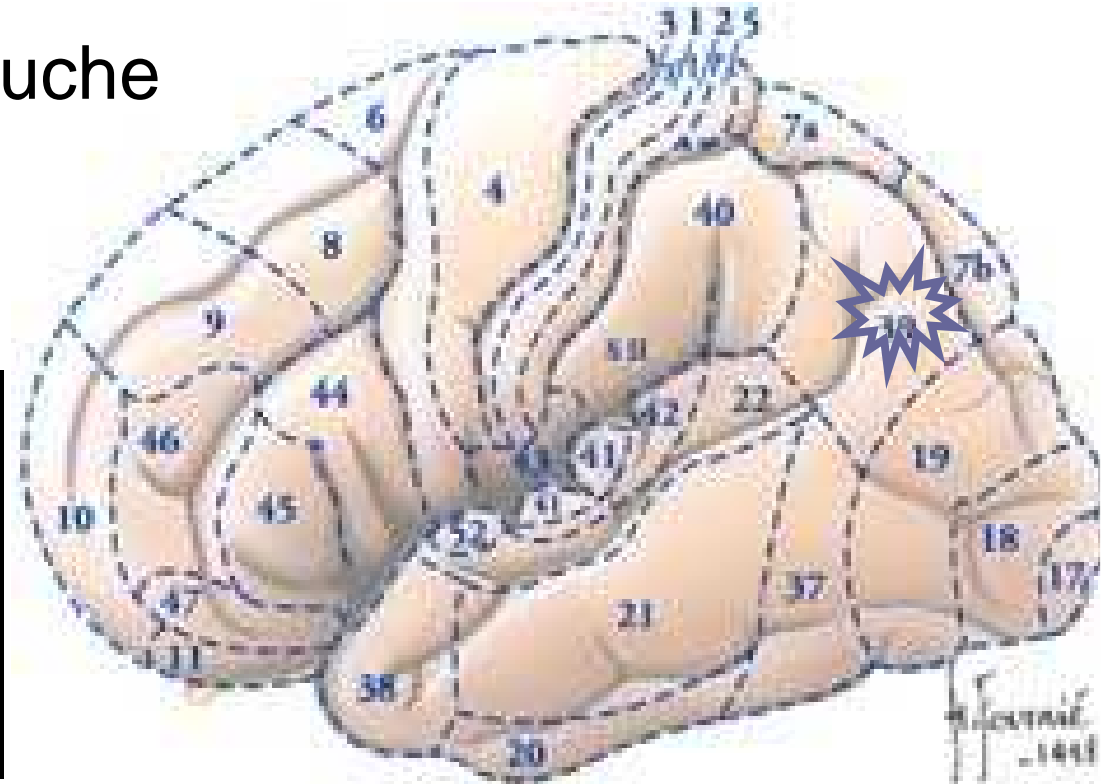
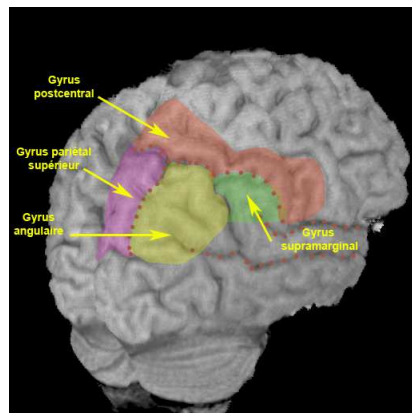
Pariétal : Praxies

- Idéomotrice
 - Intransitifs, symboliques
 - PG
- Idéatoire
 - Enchaînements de gestes simples (bougie)
- Constructive
 - Ppost D/G
 - Dessin sur ordre verbal
- Bucco-faciale, habillage, marche



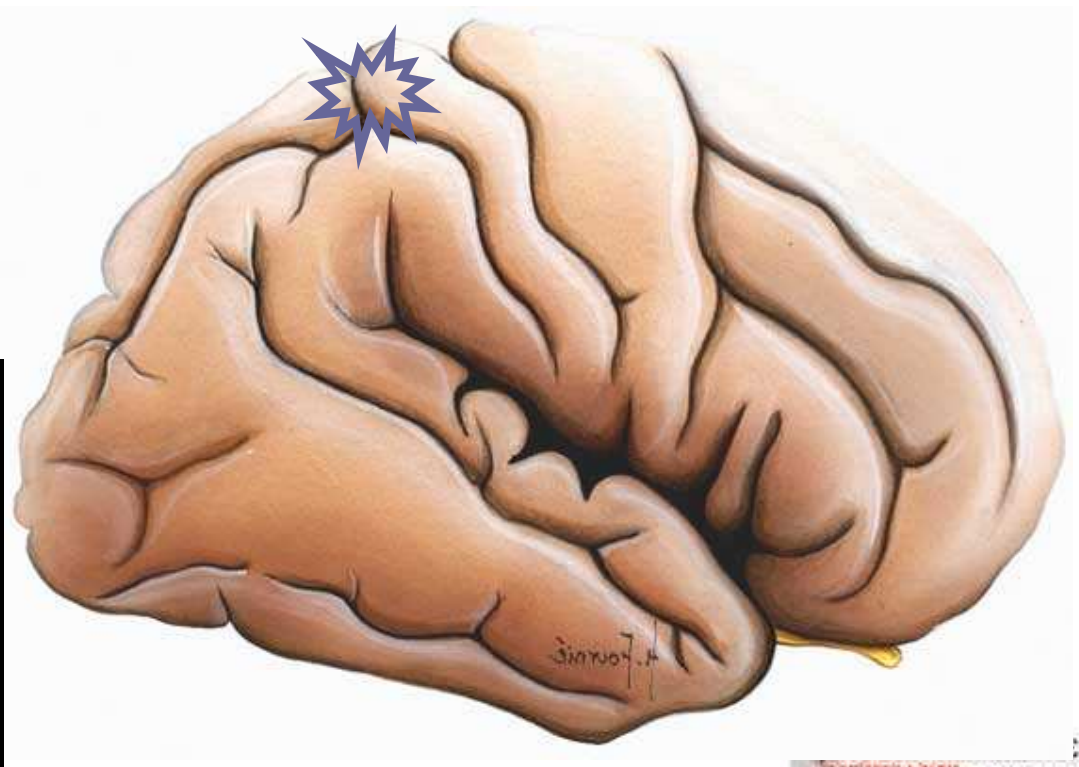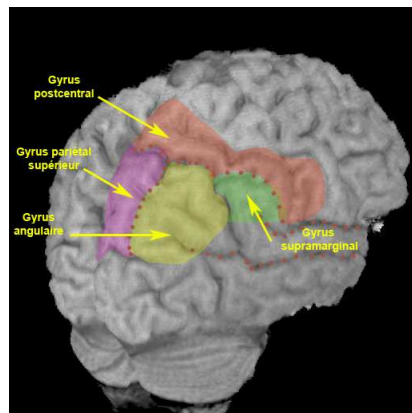
Syndrome de Gerstmann

- Gyrus angulaire (39) - Gauche
- Indistinction droite-gauche
- Agnosie digitale
- Acalculie
- Agraphie

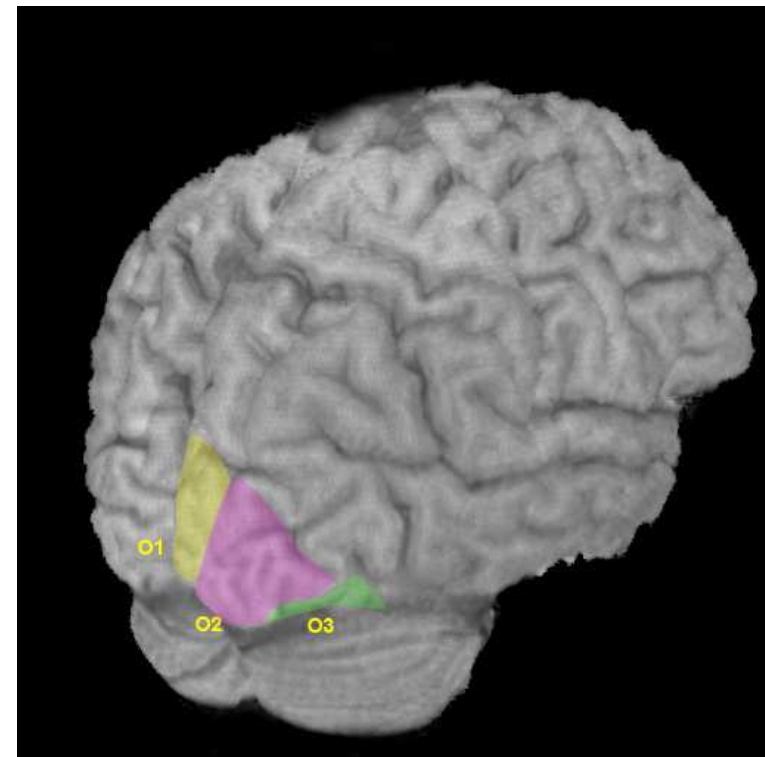
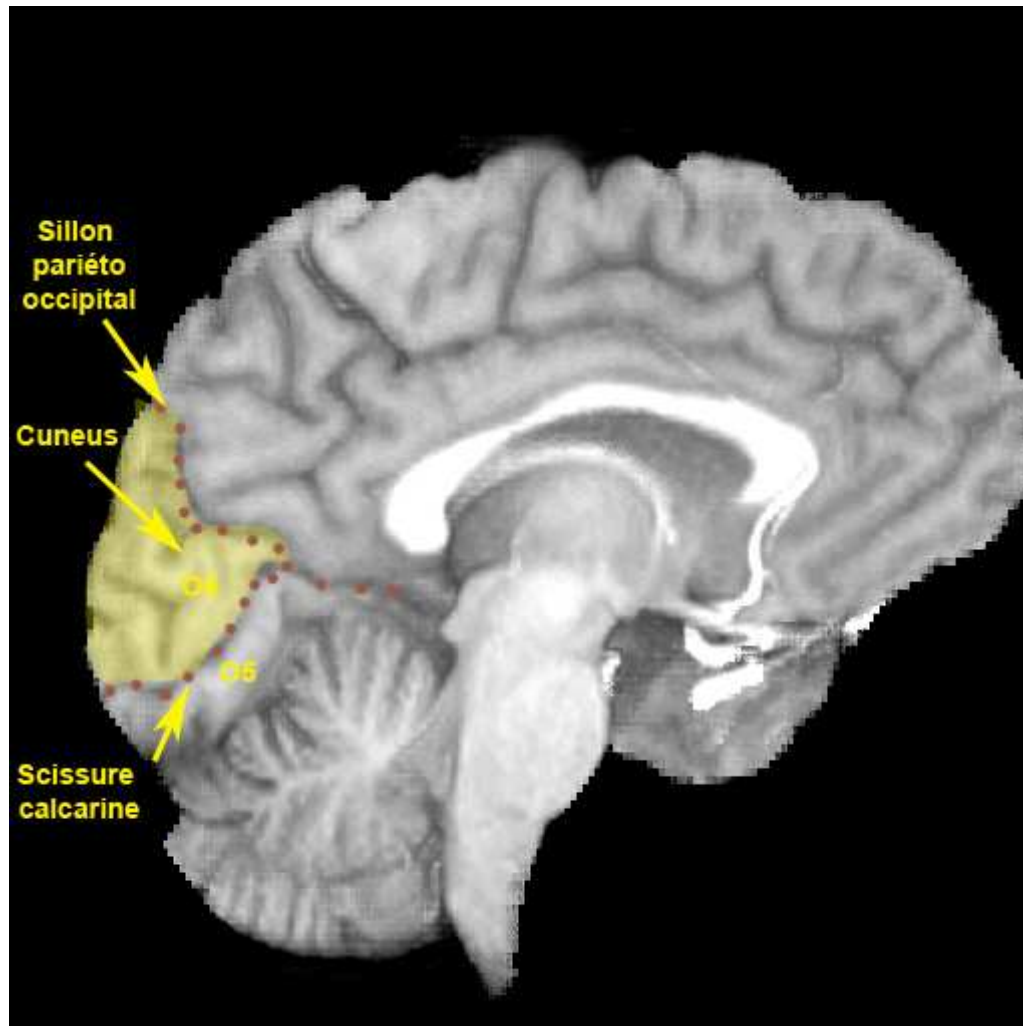


Syndrome d'Anton-Babinski

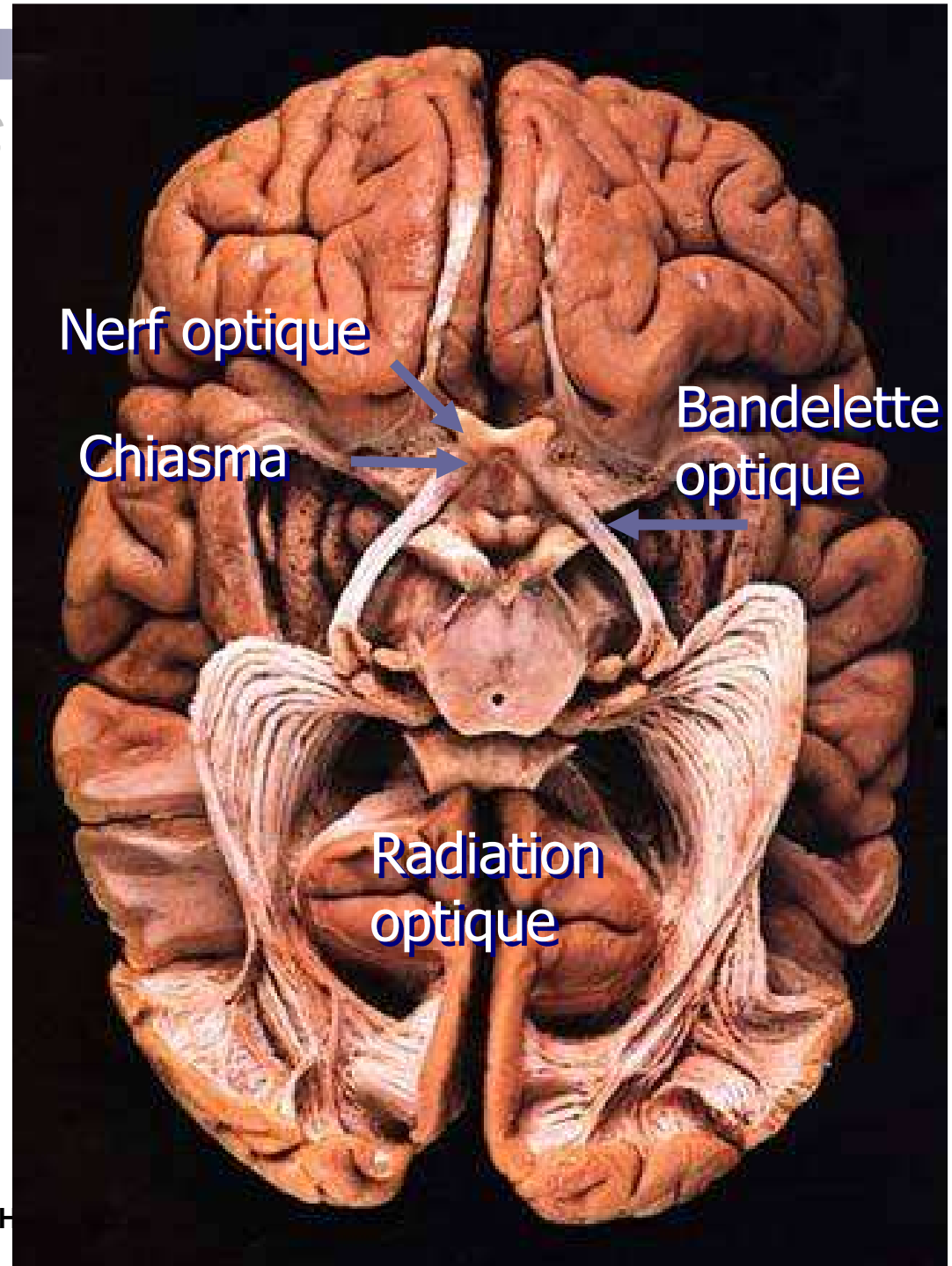
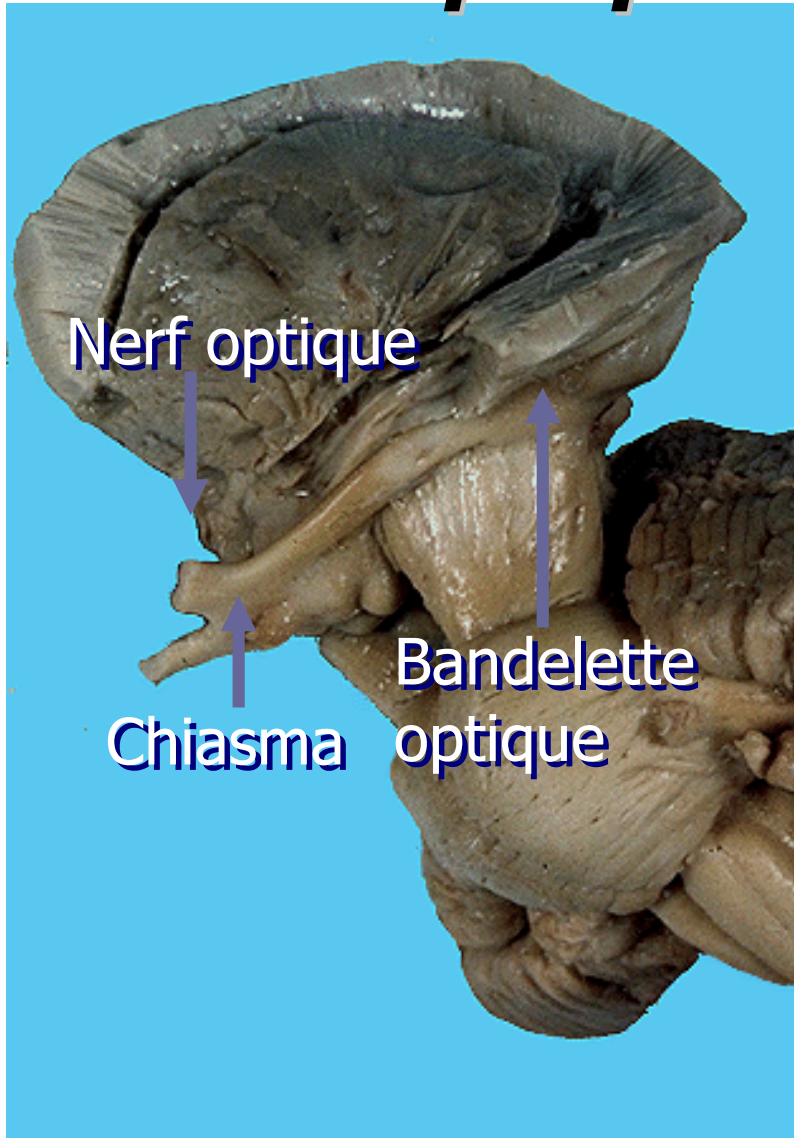
- cortex somato-gnosique droit (aire 5)
- Hémiasomatognosie
- Anosodiaphorie
- Anosognosie



Occipital

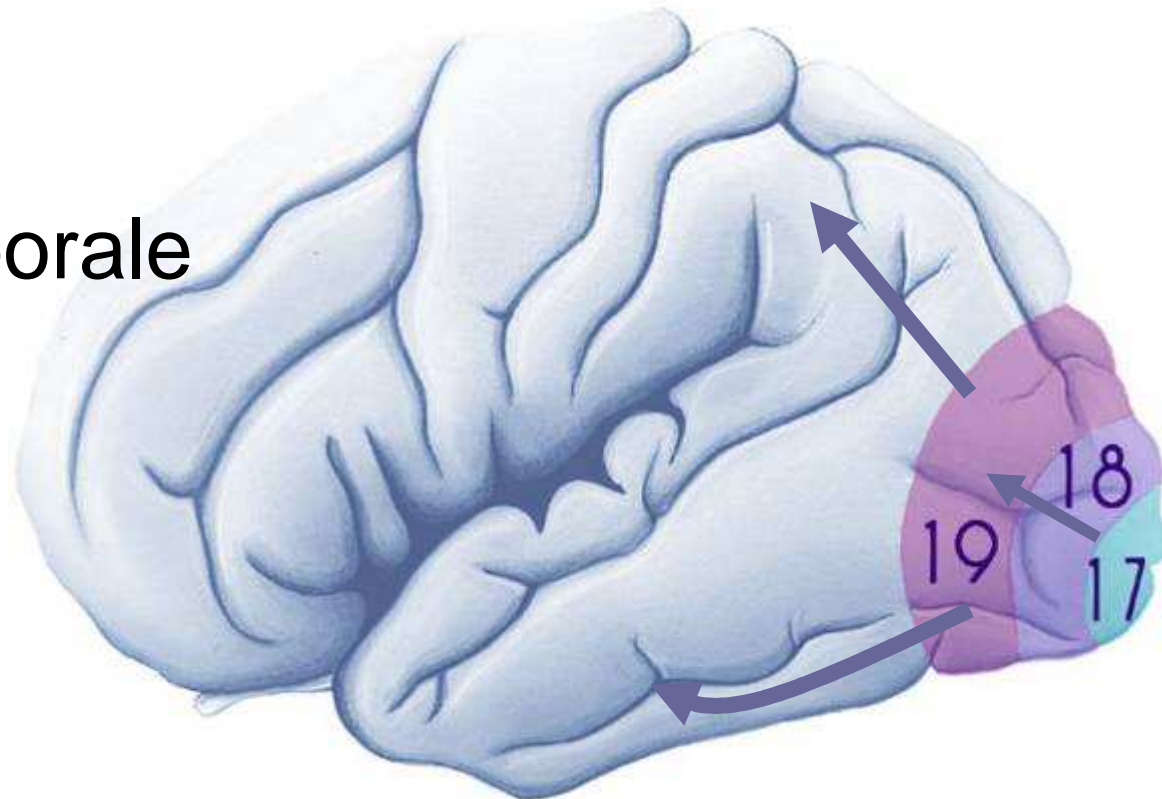
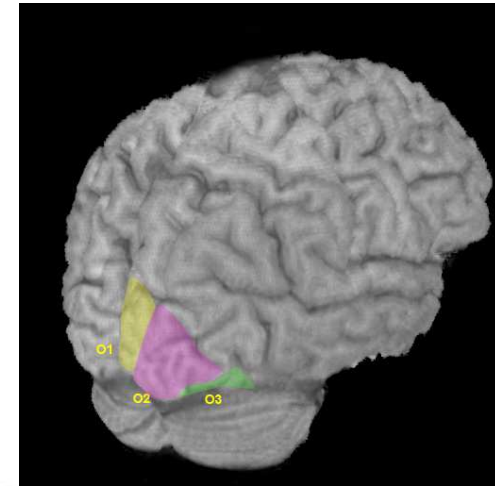


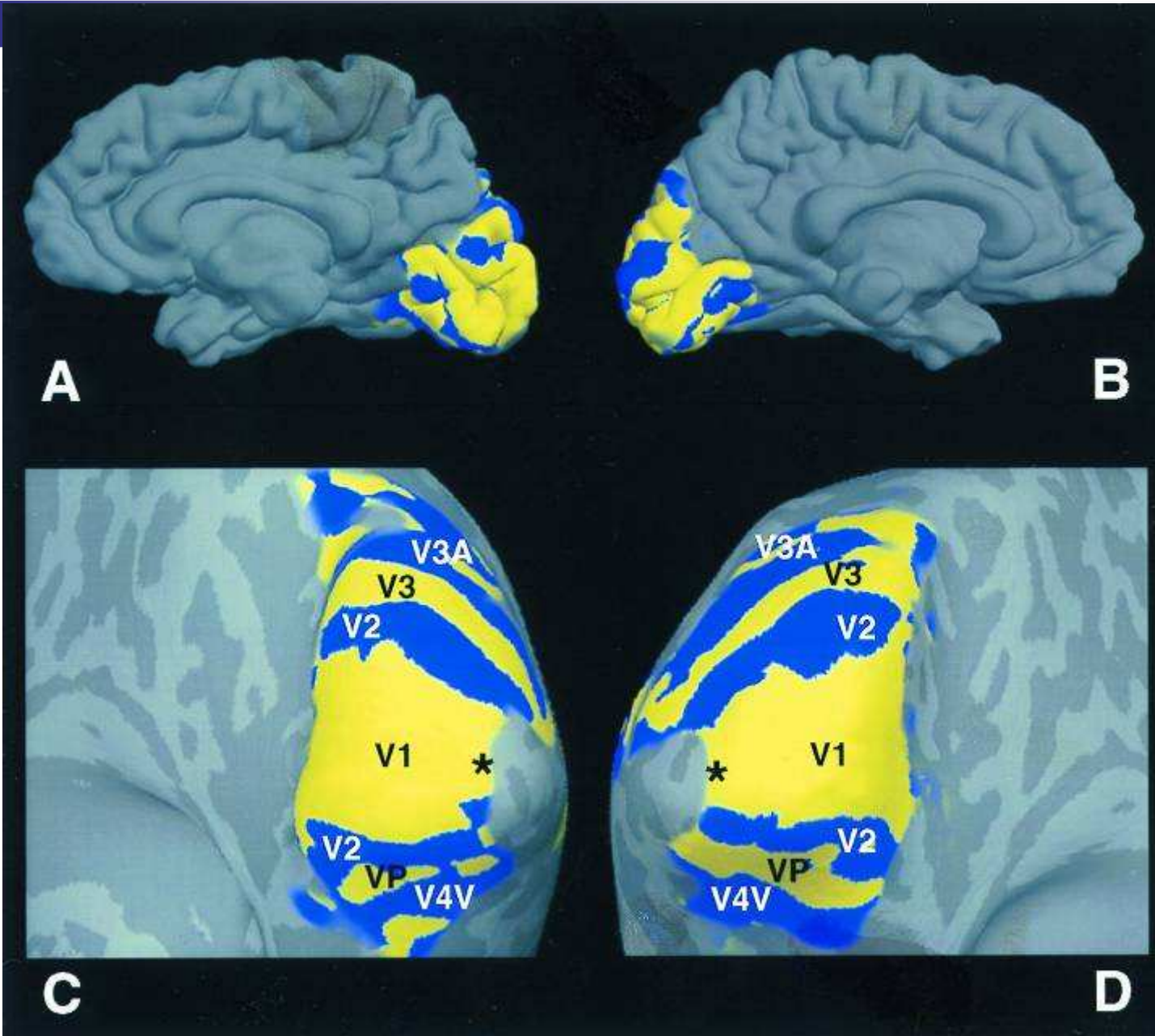

Voies optiques




Cortex visuel

- V1 : 17
- V2 : 18
- V3- V4 : 19
- Aire inféro-temporale
- Aire pariétale postérieure



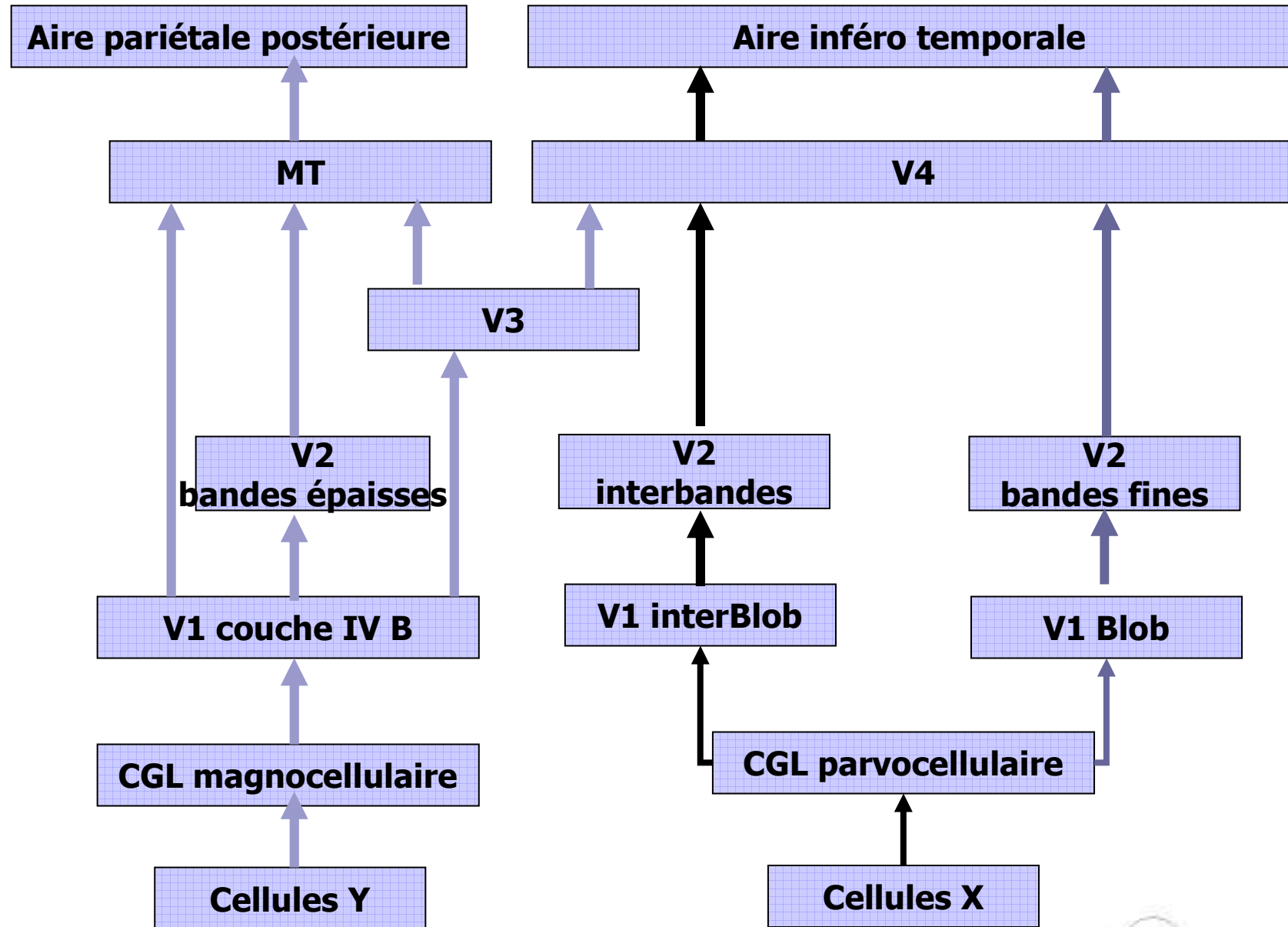




Localisation

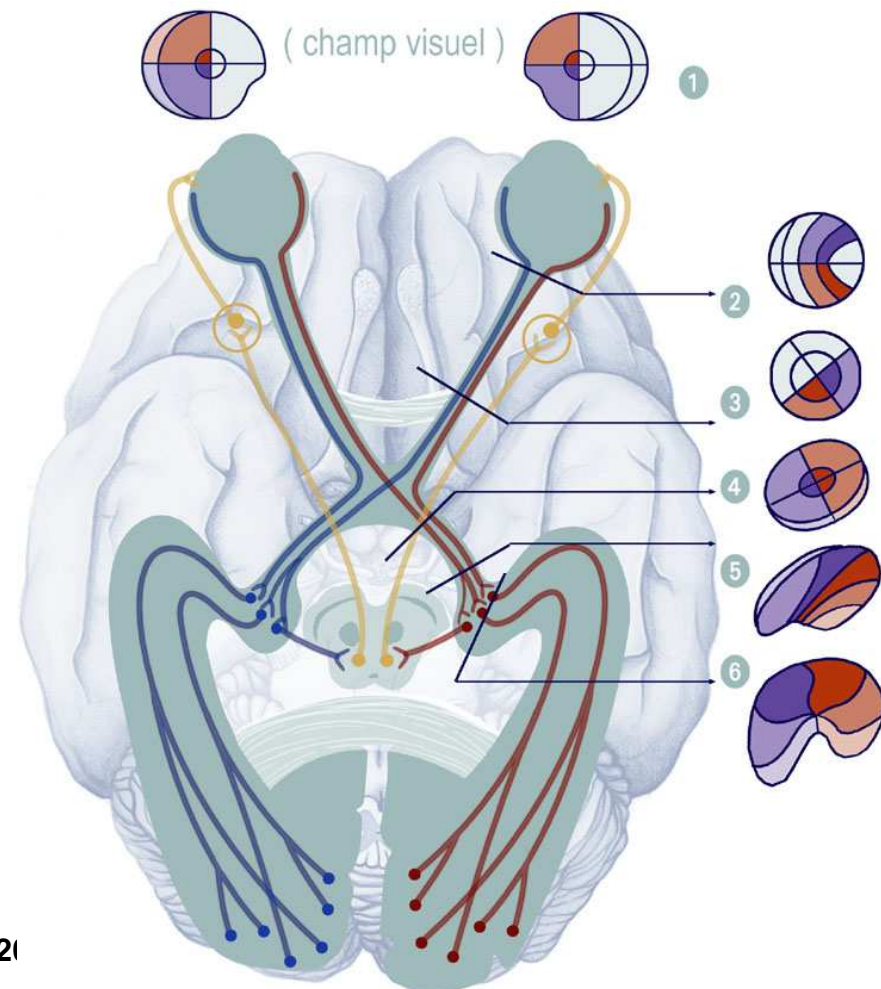
Description

couleur



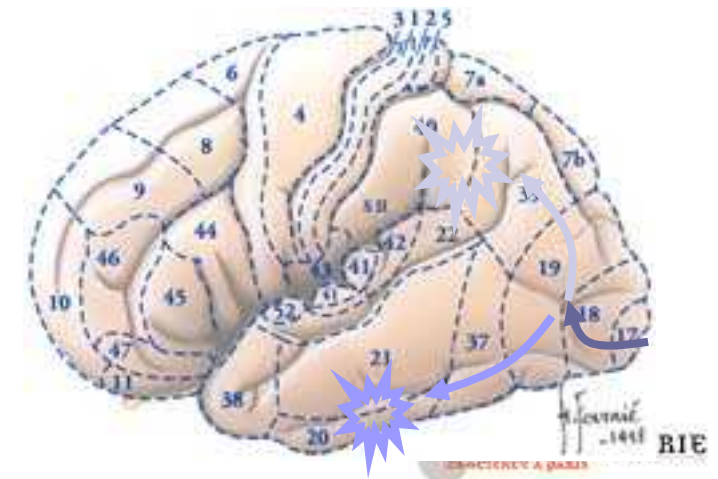
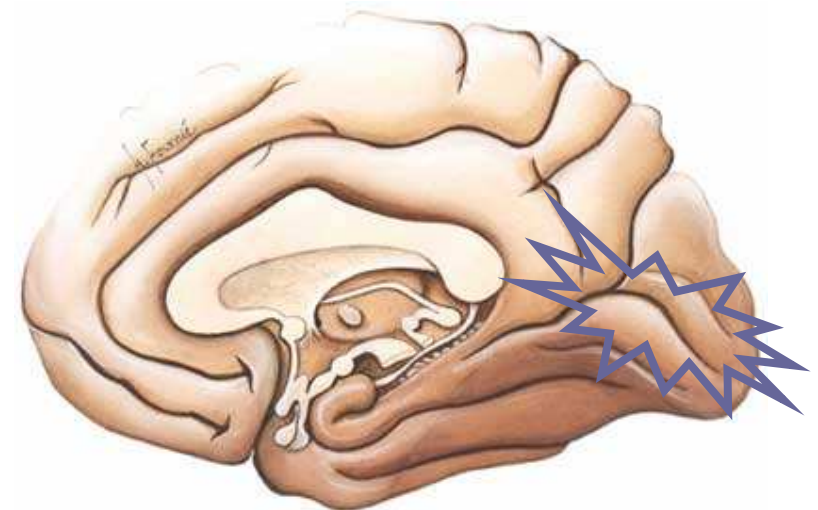
Clinique

- II : Cécité monoculaire
- Bandelette optique :
HLH avec RPM -
- Chiasma optique : H
BiTemporale
- Radiations optiques :
QLH avec RPM +



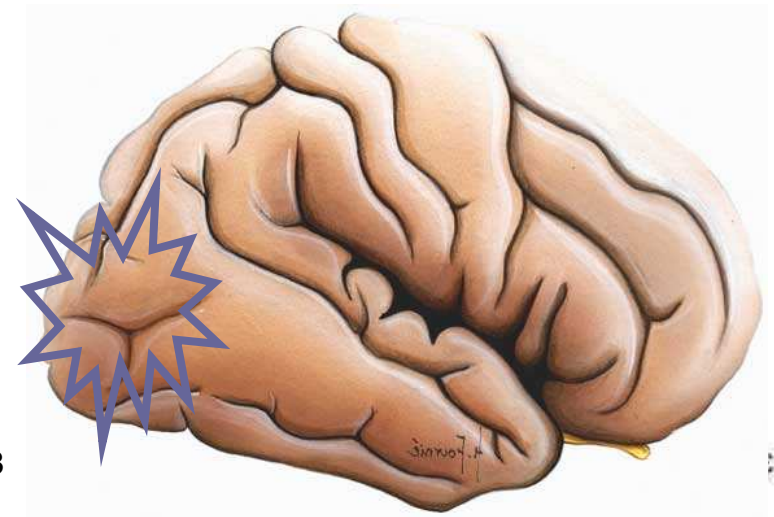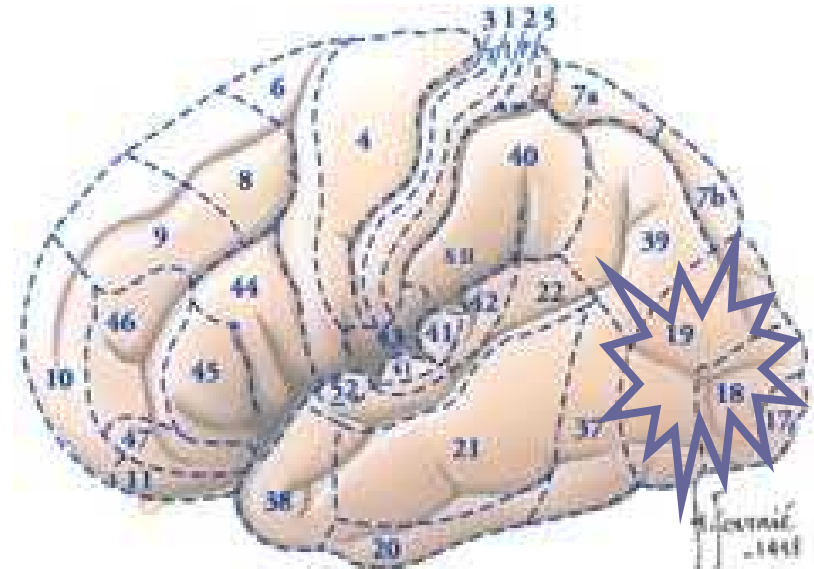
Occipital

- unilatérale
 - hémianopsie latérale homonyme
 - quadranopsie
- bilatérale
 - cécité corticale conserve les réflexes pupillaires
- Crises visuelles
- agnosies
 - Agnosie visuelle
 - Objets, images, couleurs
 - prosopagnosie



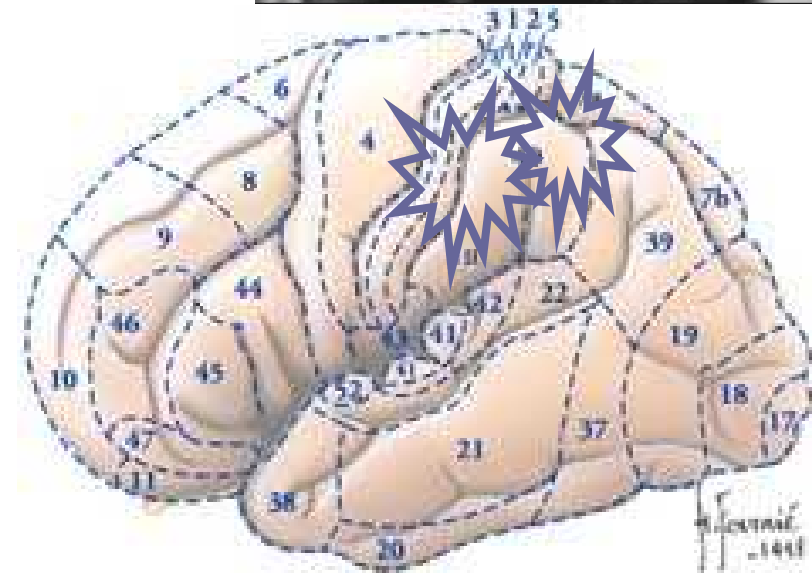
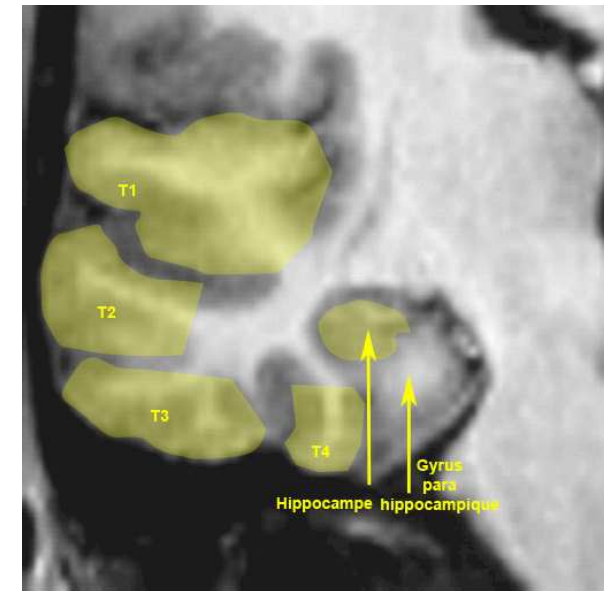
Syndrome de Balint

- Lésion bilatérale cortex visuo-gnosique 18-19
- apraxie du regard
 - diriger le regard vers un stimulus périphérique
- Asimultagnosie
 - vue d'ensemble
- ataxie optique
 - saisir un objet périphérique

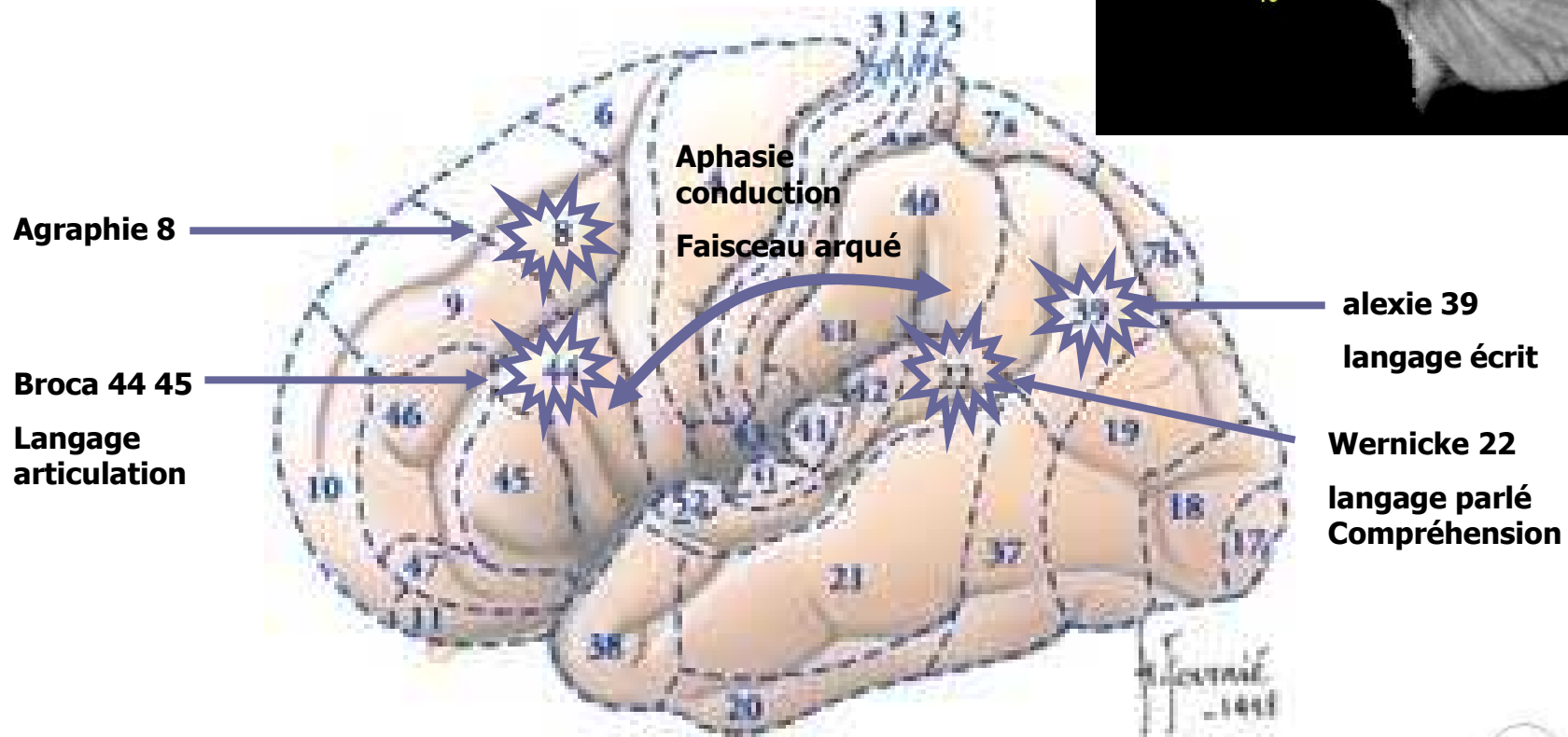
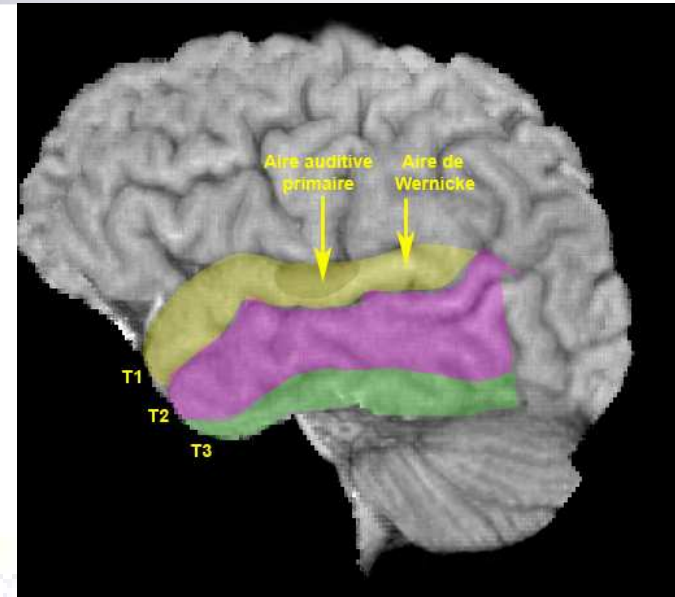



Temporal (latéral)

- Aires primaires 41 et 42
 - Déficits
 - Gauche : surdit  verbale
 - Droite : agnosie auditive
 - bilat rale : surdit  corticale
 - crises
 - Illusions, hallucinations auditives
- Aphasie de Wernicke

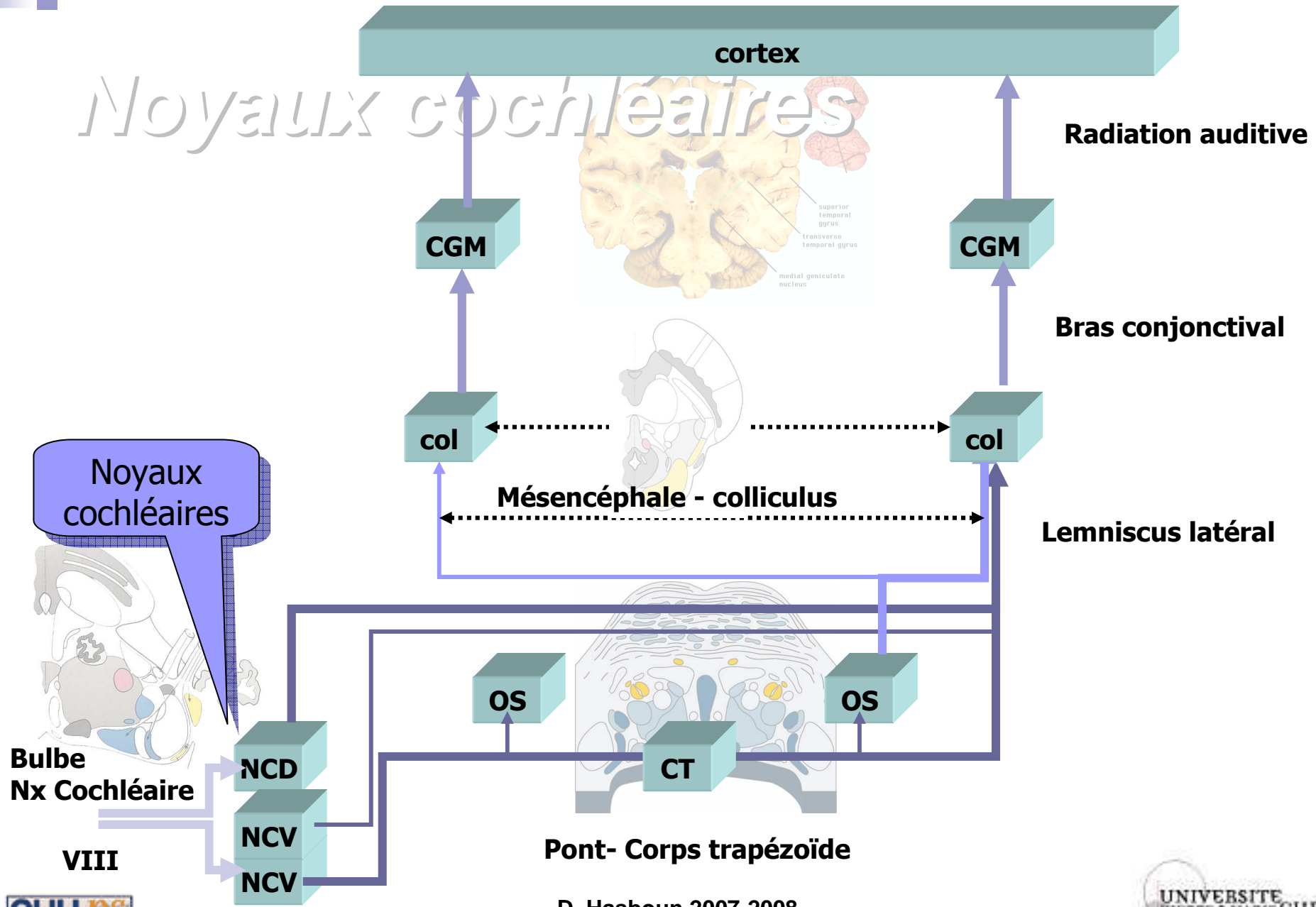


Langage



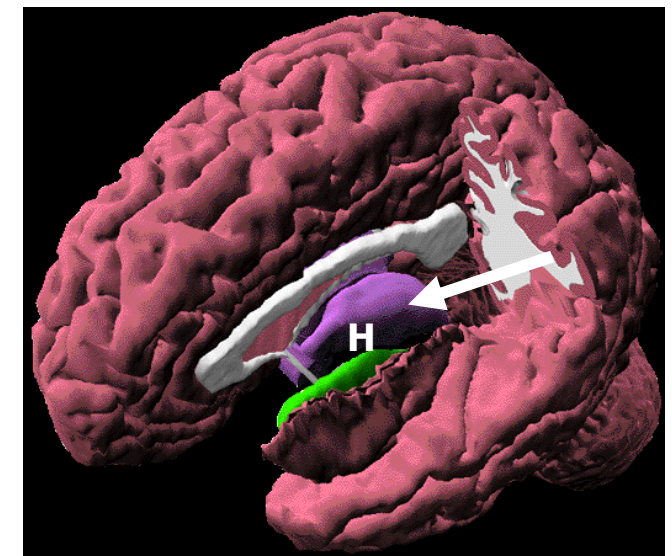
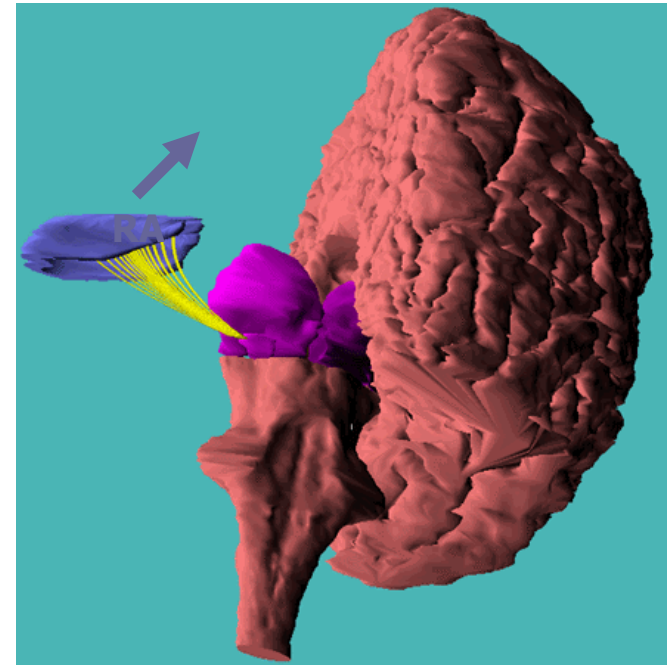


Noyaux cochléaires



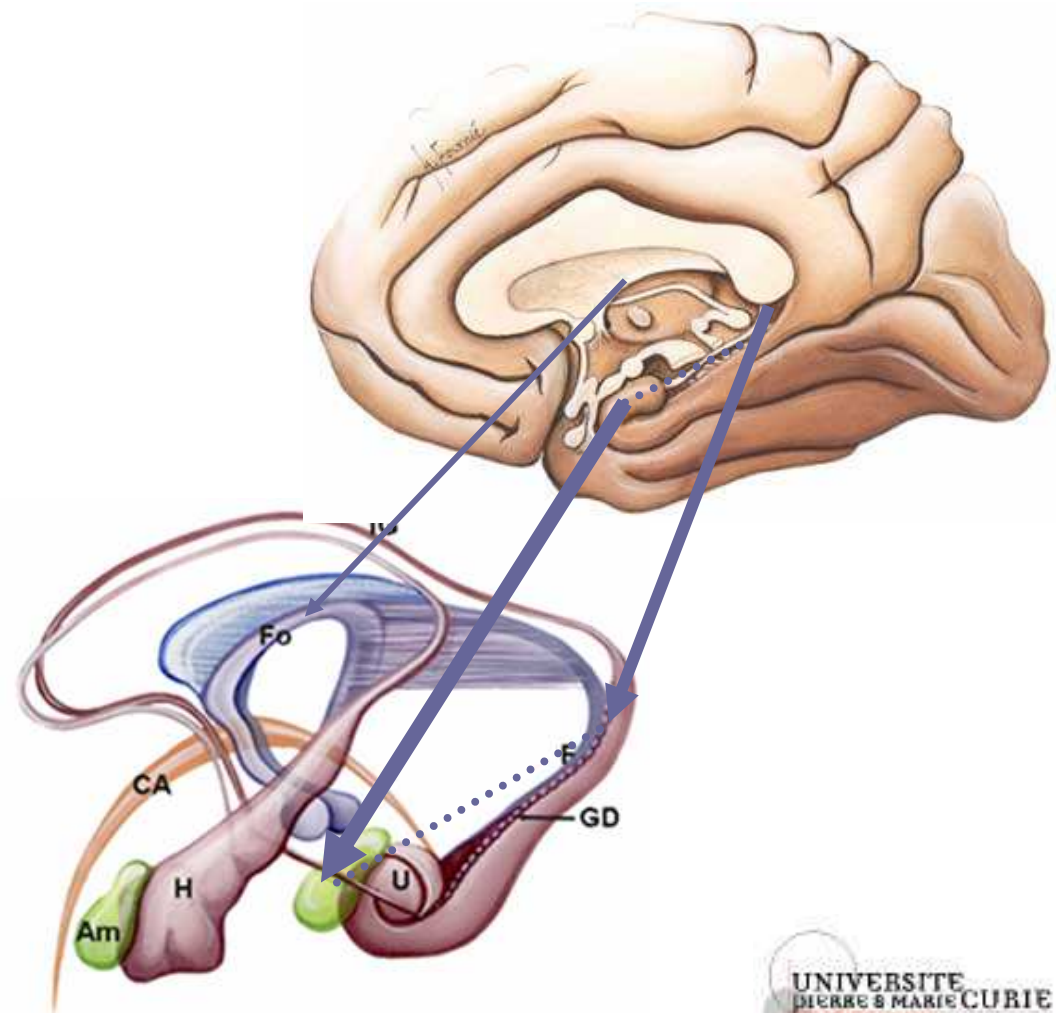
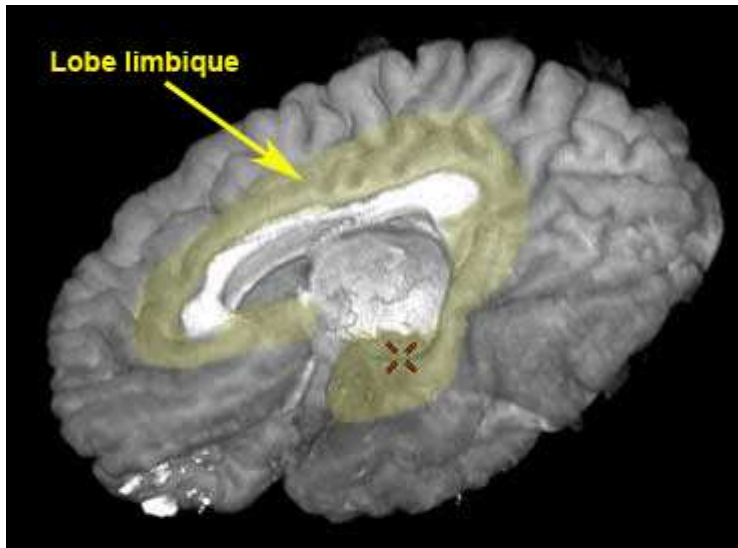
Cortex auditif

- Radiations auditives (RA)
 - CGM -> T1
- Cortex
 - Gyrus temporal transverse de Heschl (H) : 41, 42
 - Gyrus temporal supérieur : 22
 - Planum temporale
- Tonotopie
- Afférences binauriculaires



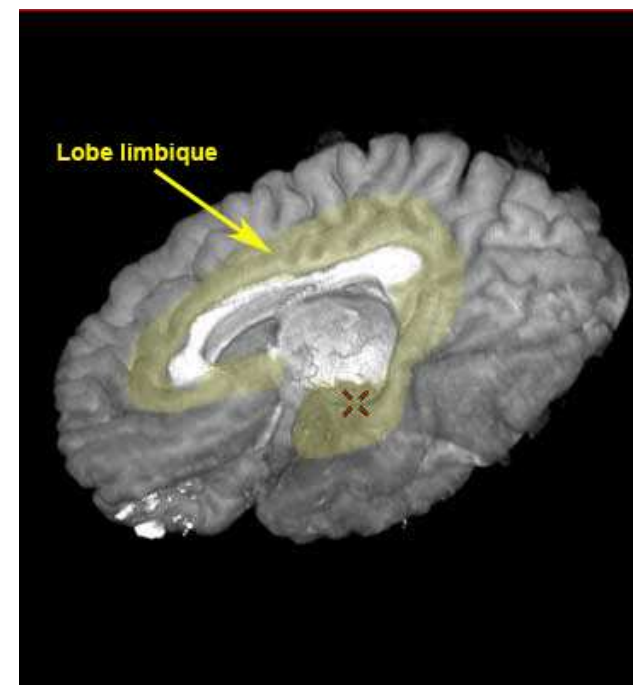
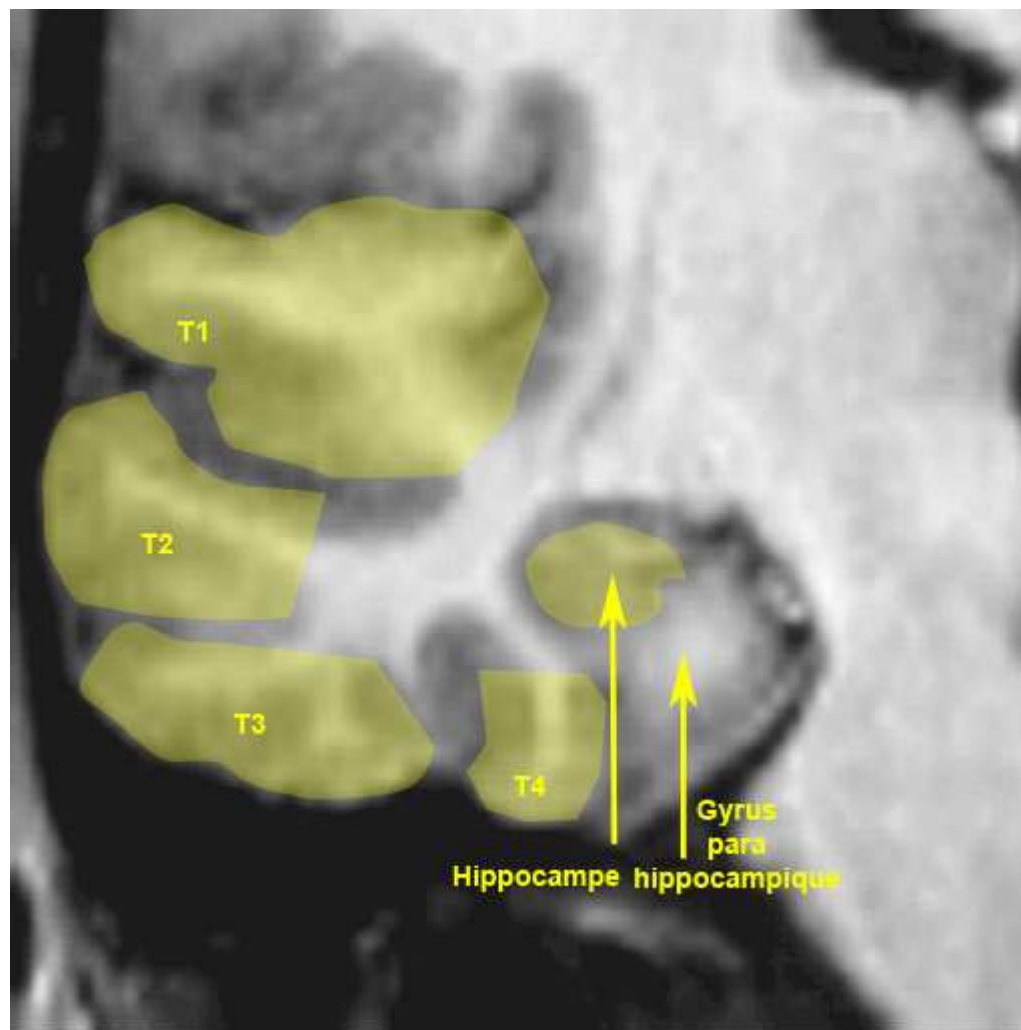
Temporal (médial)

- Crises temporelles mésoiales
 - Aura épigastrique
 - Étrangeté, déjà vu...
 - Troubles de la conscience
 - Automatismes
 - Olfactives : amygdale

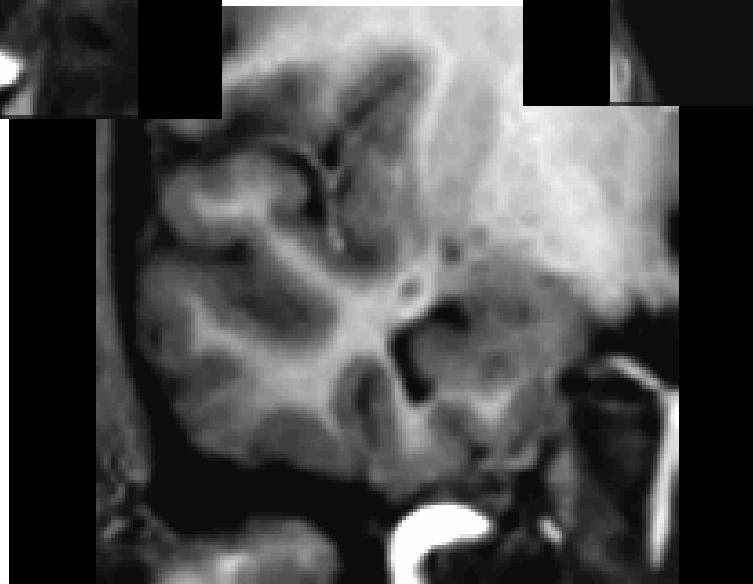
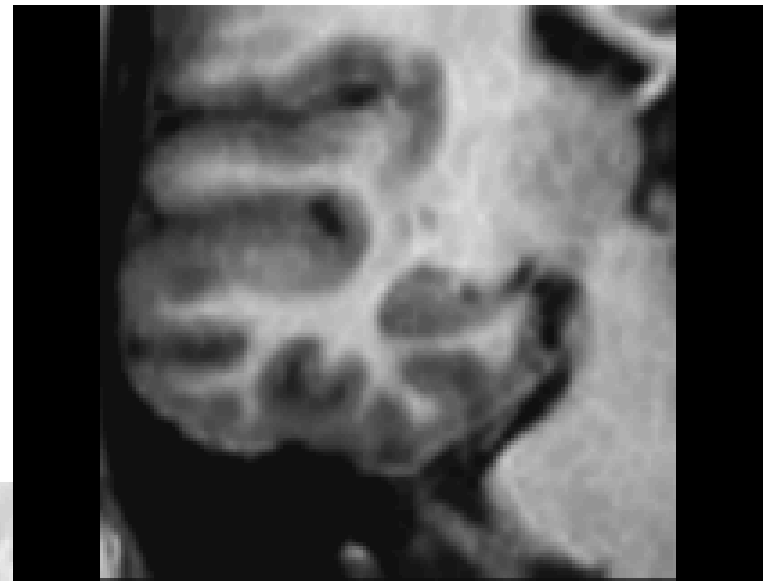
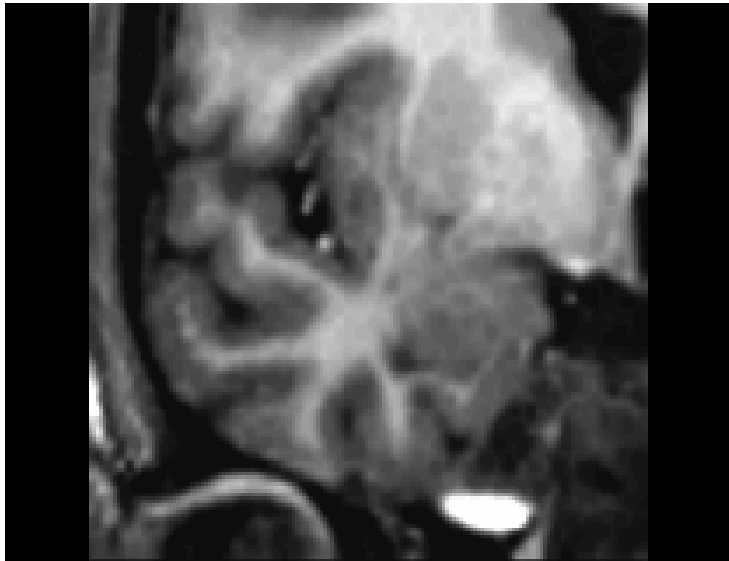D. H

Temporal

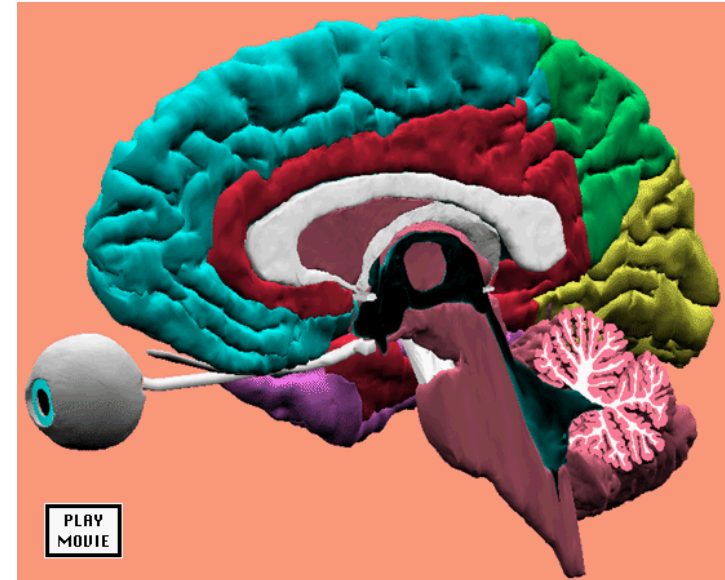


Temporal (médial)

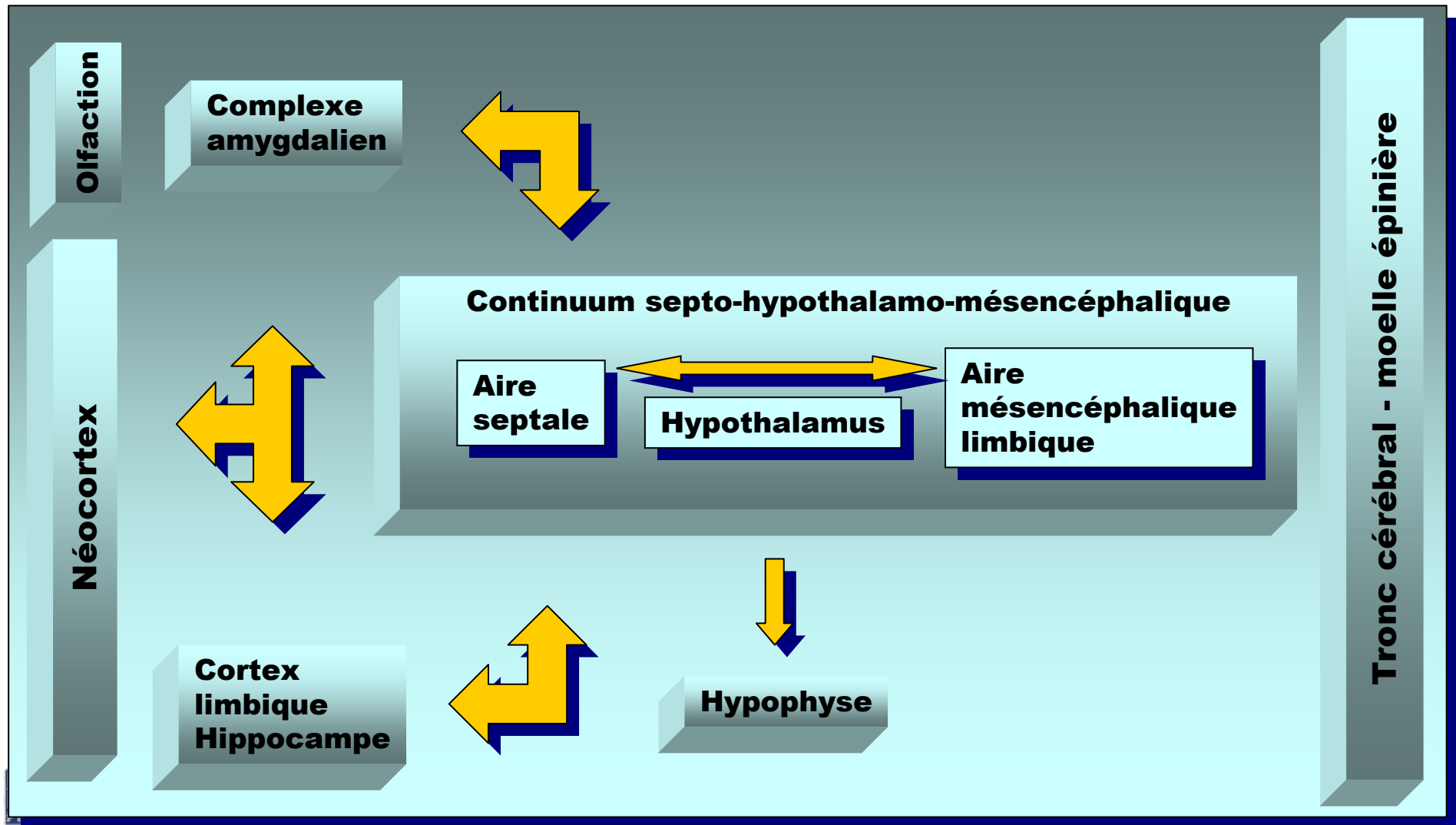


Systeme limbique

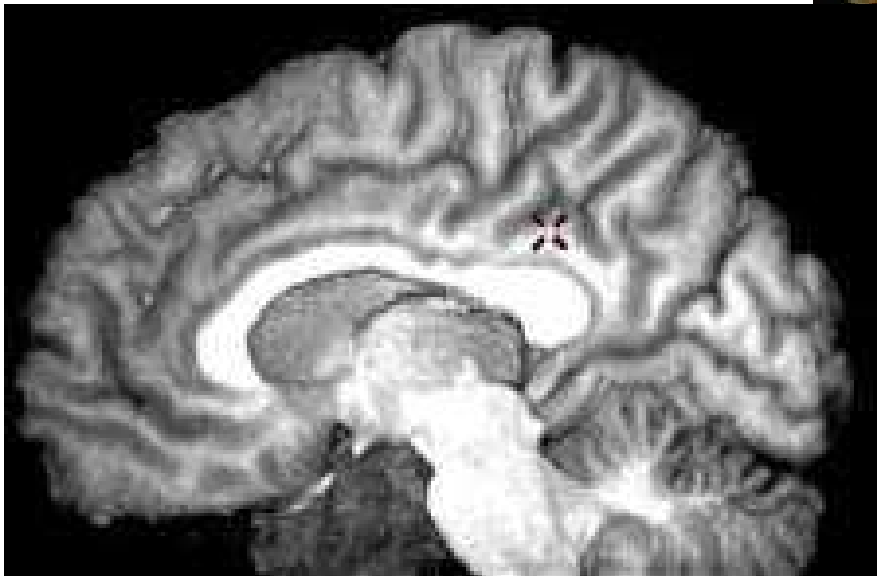
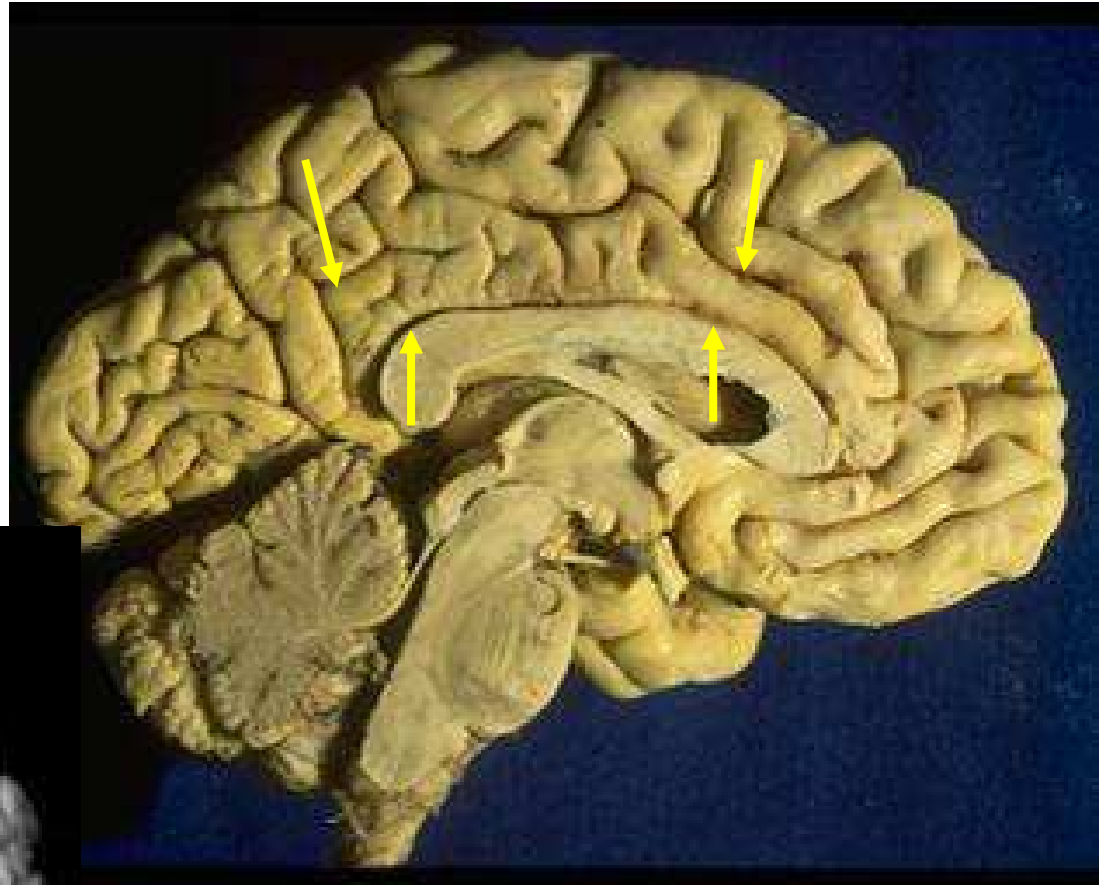
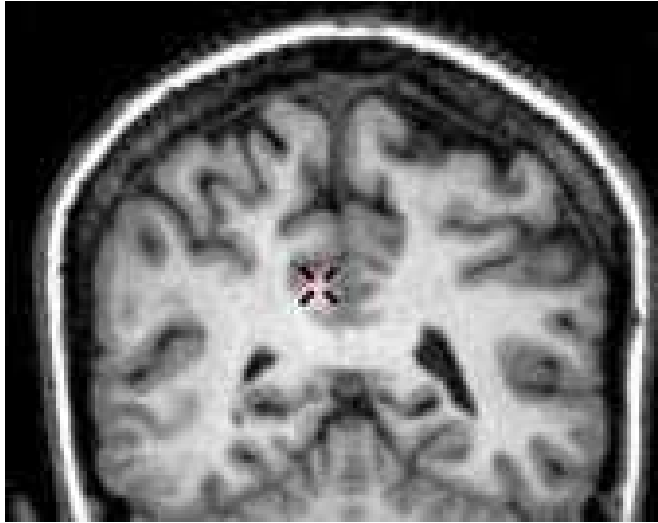
- Broca (1877) « la raquette olfactive- Grand Lobe Limbique »
- Papez (1937) - 'Limbic Circuit' - emotion
- MacLean (1952) - cerveau tri-unitaire :
 - reptilien : TC NGC
 - paléo-mammalien : Systeme Limbique
 - néo -mammalien : néocortex
- Nauta (1972) - 'Septo-hypothalamo-mesencephalic continuum'



Hiérarchie anatomique

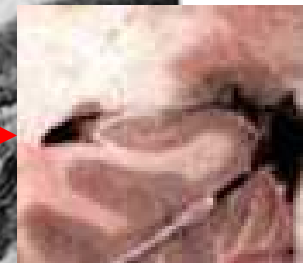
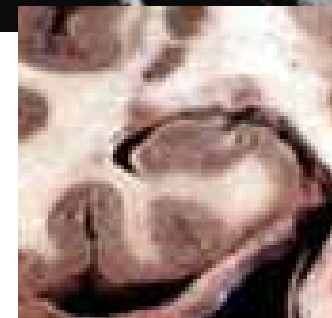
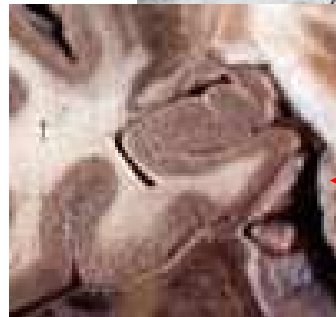
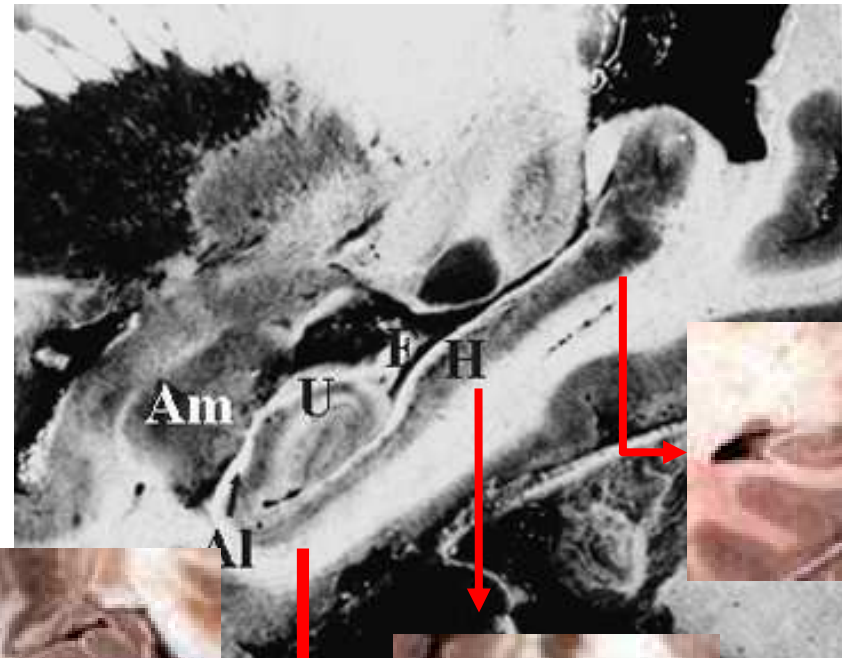
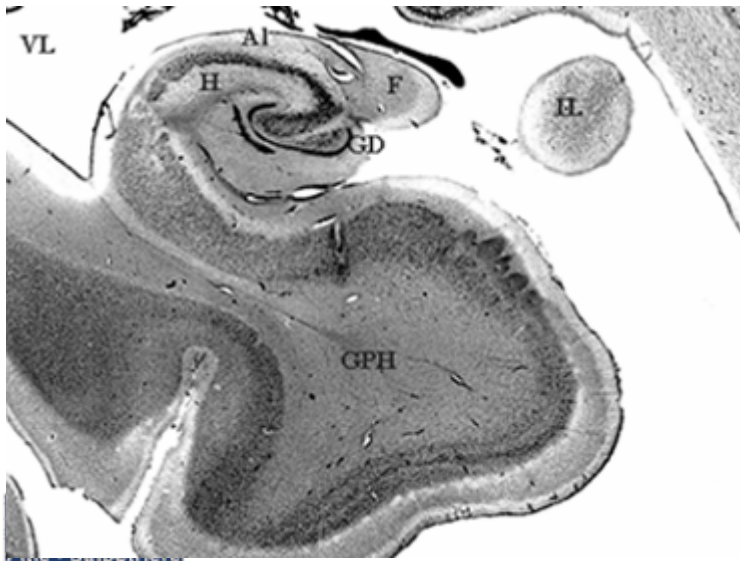
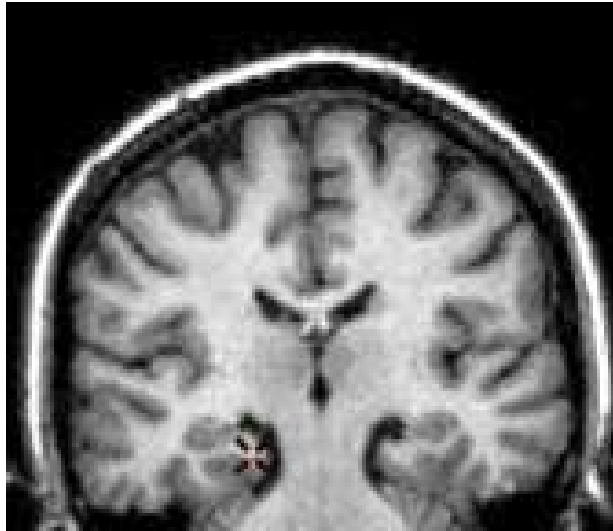


Gyrus cingulaire



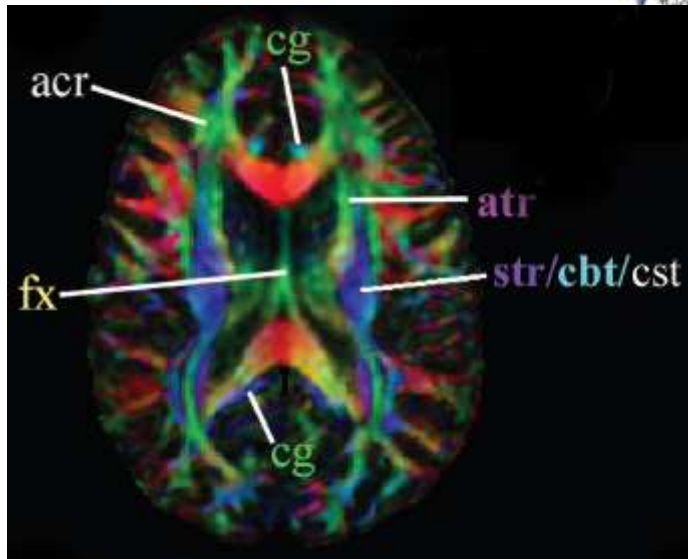
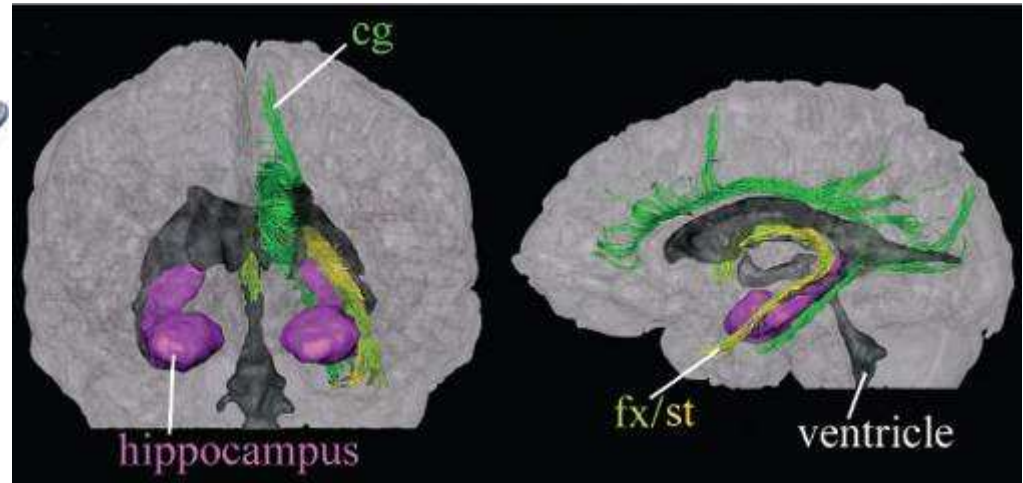
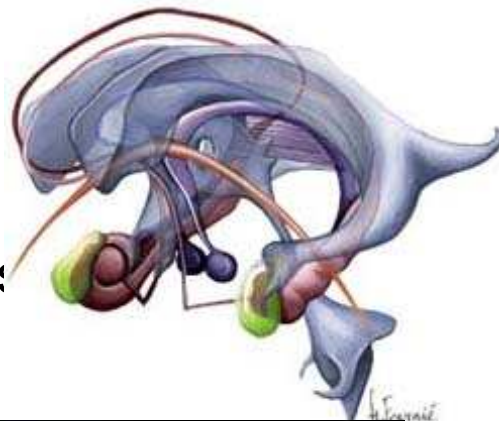
Réactions émotionnelles
24, 28, 31

Hippocampe

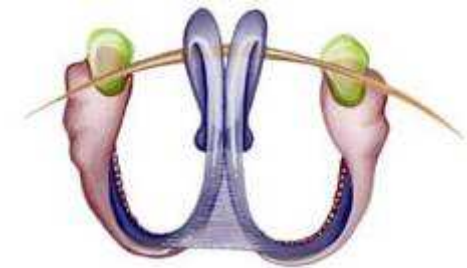


Fornix

- Mixte
- Colonne
- Corps
- Crus fornicis
- fimbria

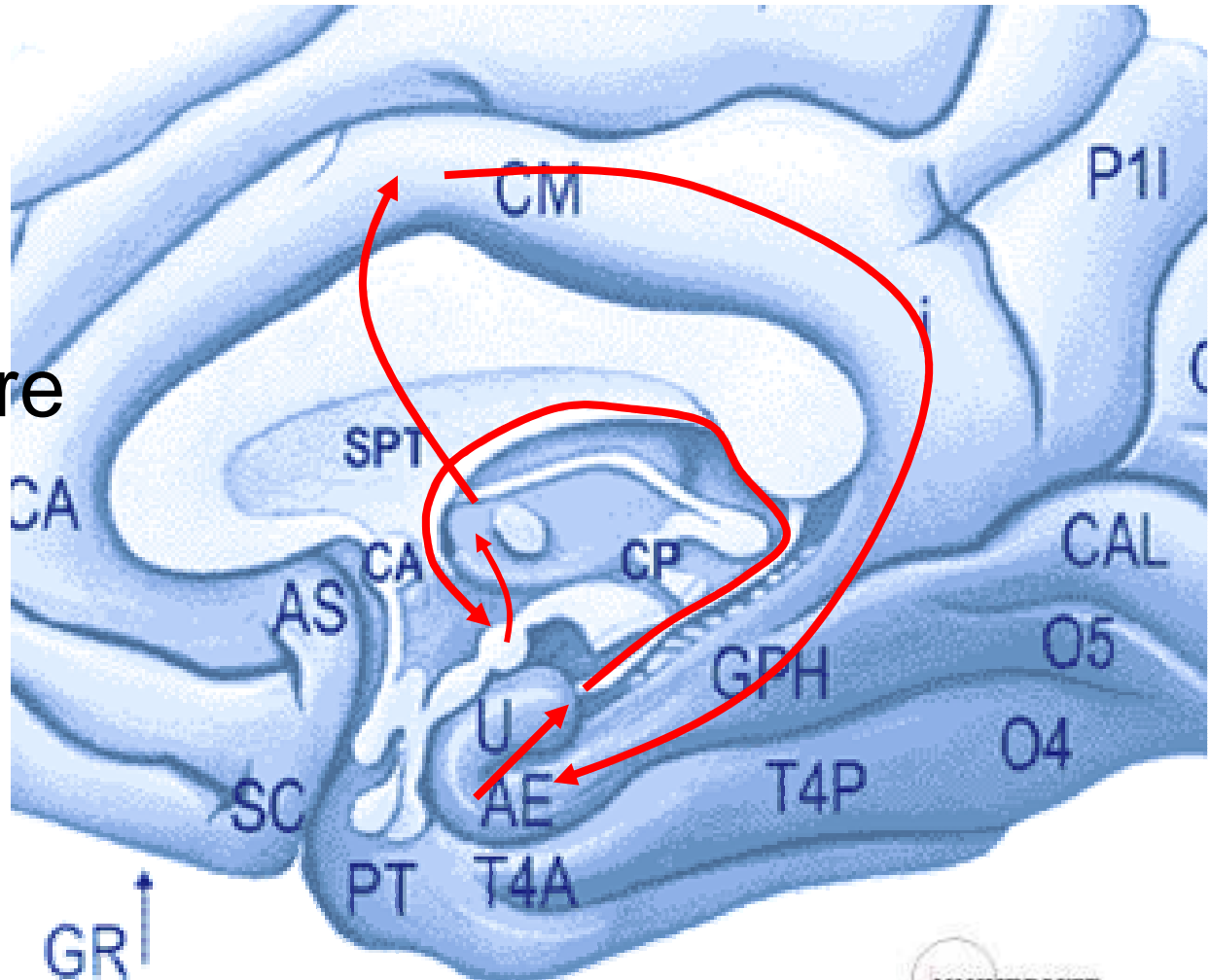


Setsu Wakana, Radiology 2004; 230:77-87



Circuit de Papez

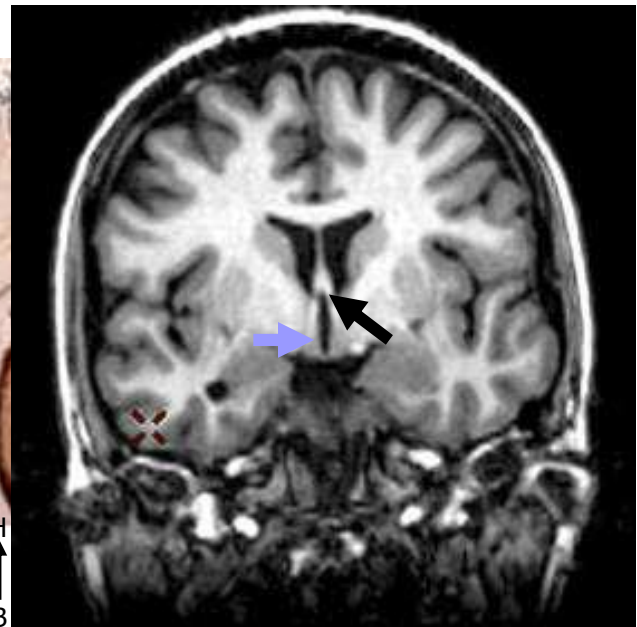
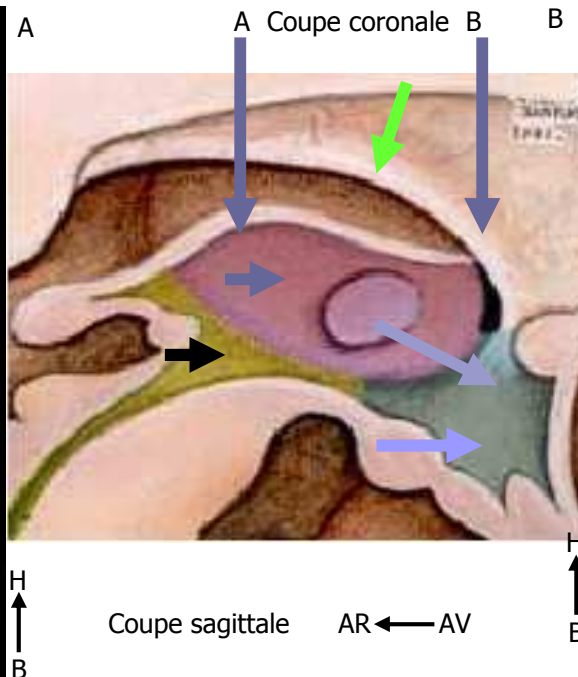
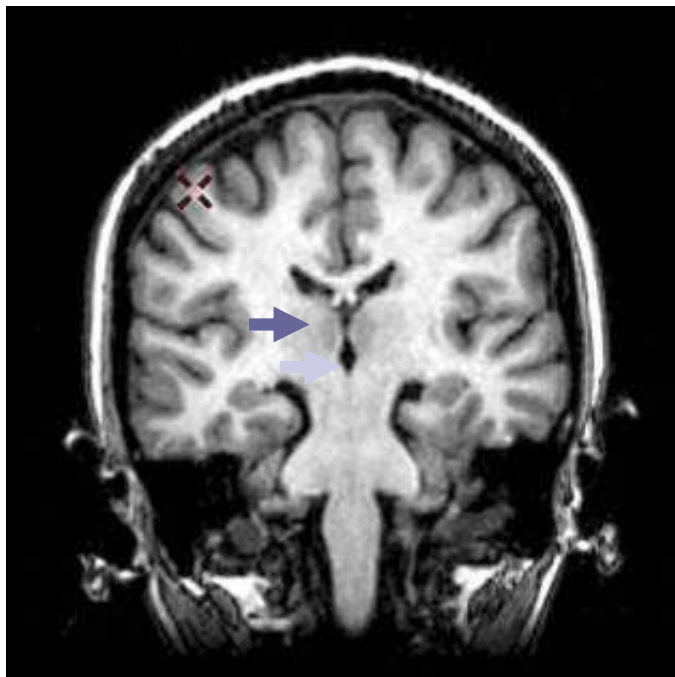
- A. Entorhinale
- Hippocampe
 - Fornix
- Corps mamillaire
 - Fx MT
- Thalamus
- G. Cingulaire
- A. Entorhinale



D. Hasboun 2007-2008

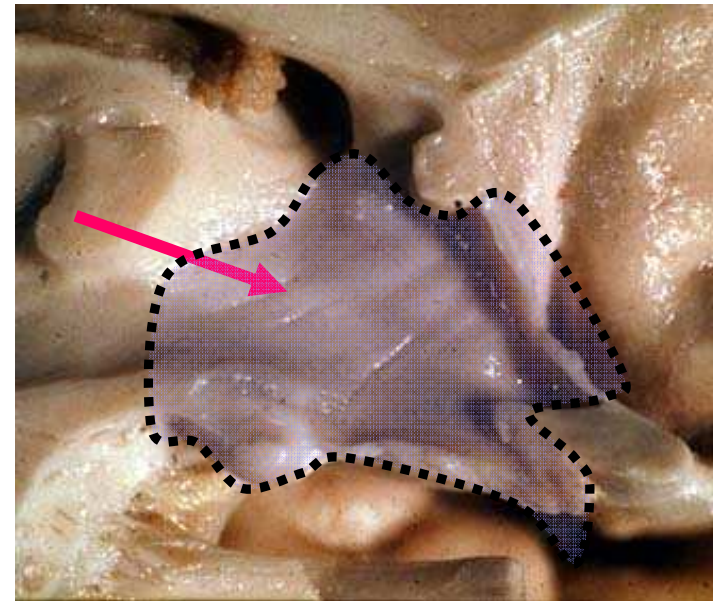
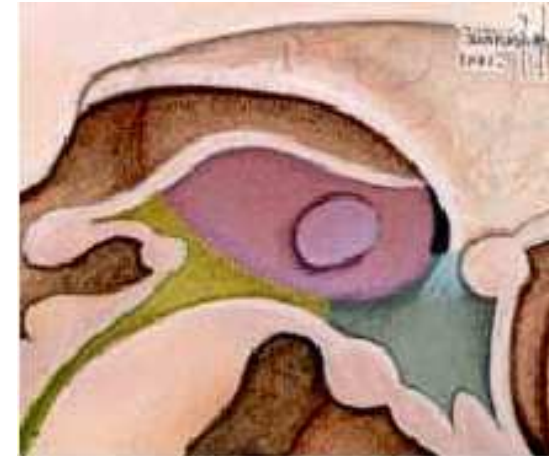
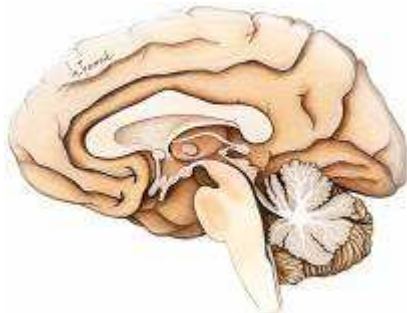
Diencéphale : contrôles et régulations

- Thalamus →
- Hypothalamus →
- Sous-thalamus →
- fornix →
- foramen interventriculaire (trou de Monro) →

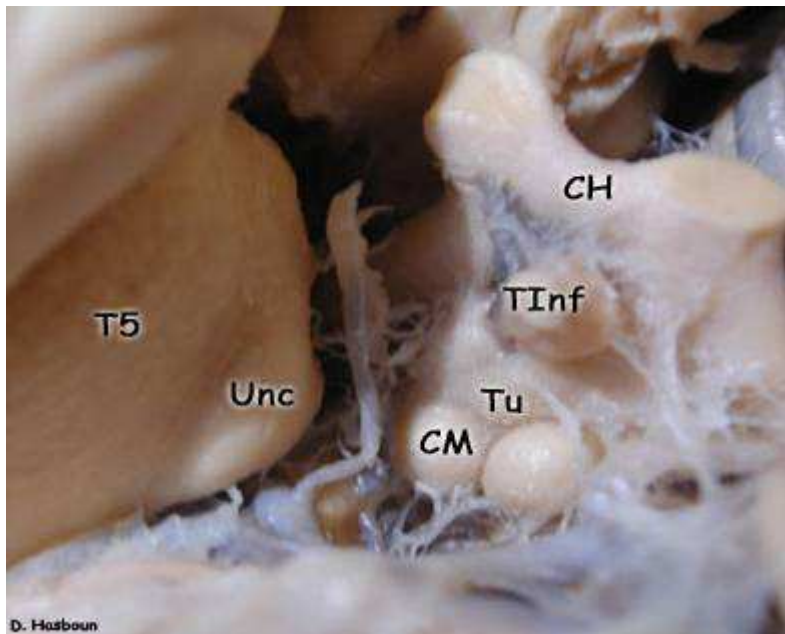
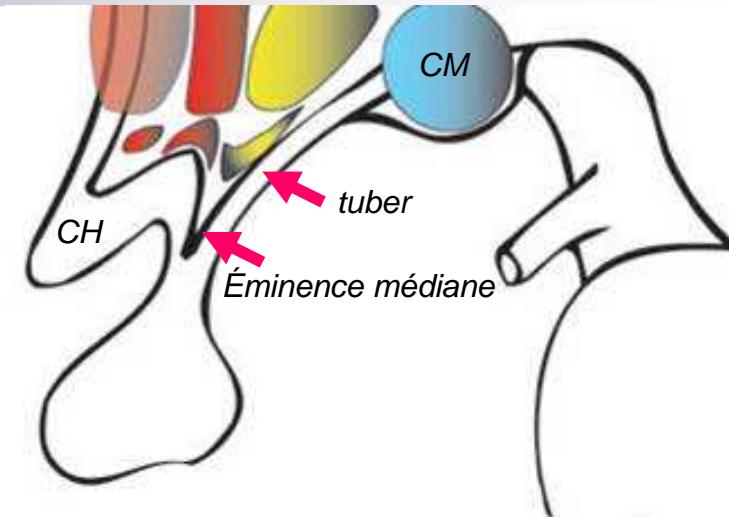


Hypothalamus

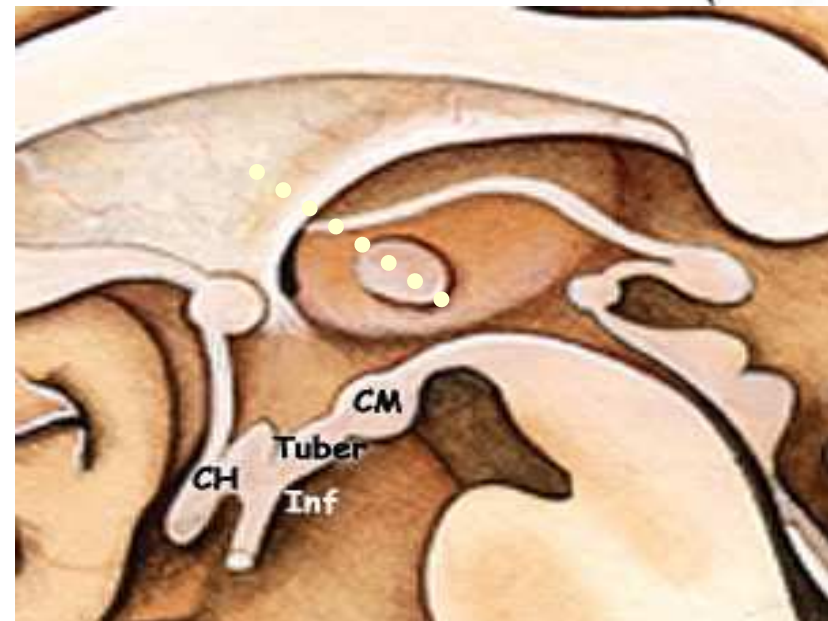
- Paroi latérale du V3
- Plancher du V3
 - En avant du thalamus
 - Sillon hypothalamique
 - En avant du Sous thalamus



Hypothalamus



D. Hasboun



Vascularisation

■ voies d'apport

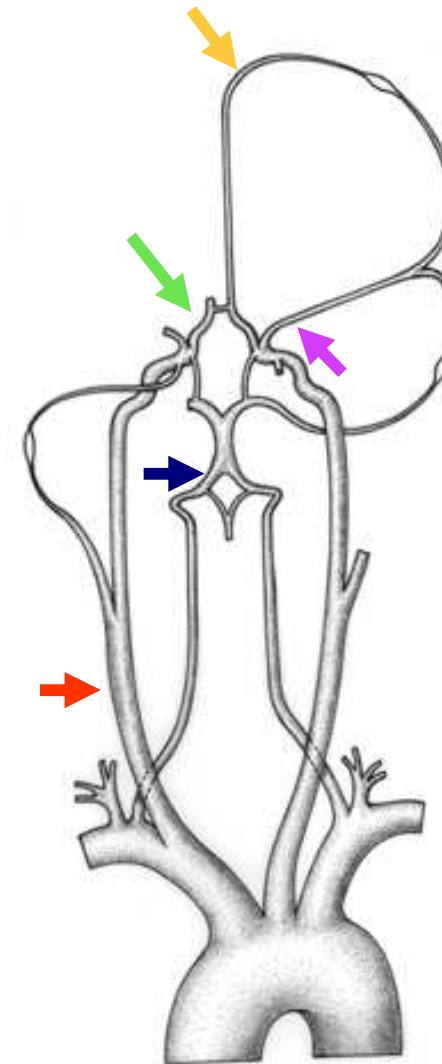
- Artères carotides internes →
- Artères vertébrales et **tronc basilaire** →

■ polygone de Willis →

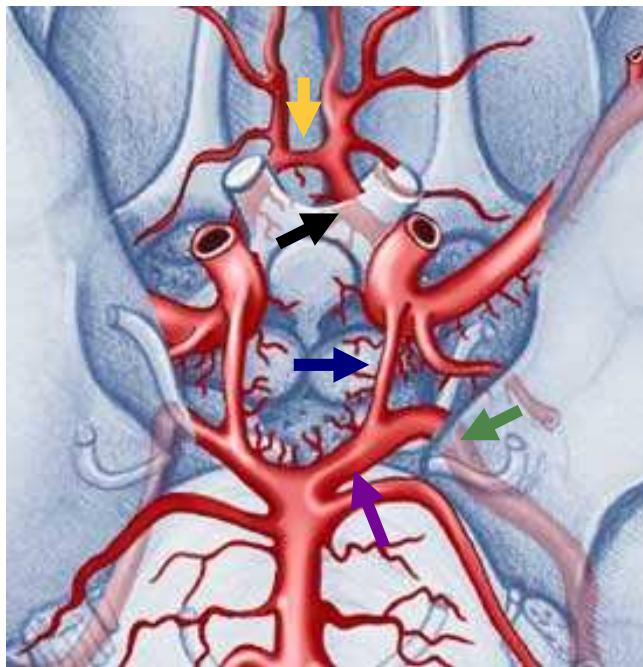
■ artères cérébrales

- *trajet basal* →
- *trajet périphérique* →

■ anastomoses



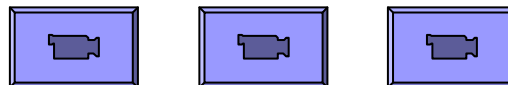
Polygone de Willis



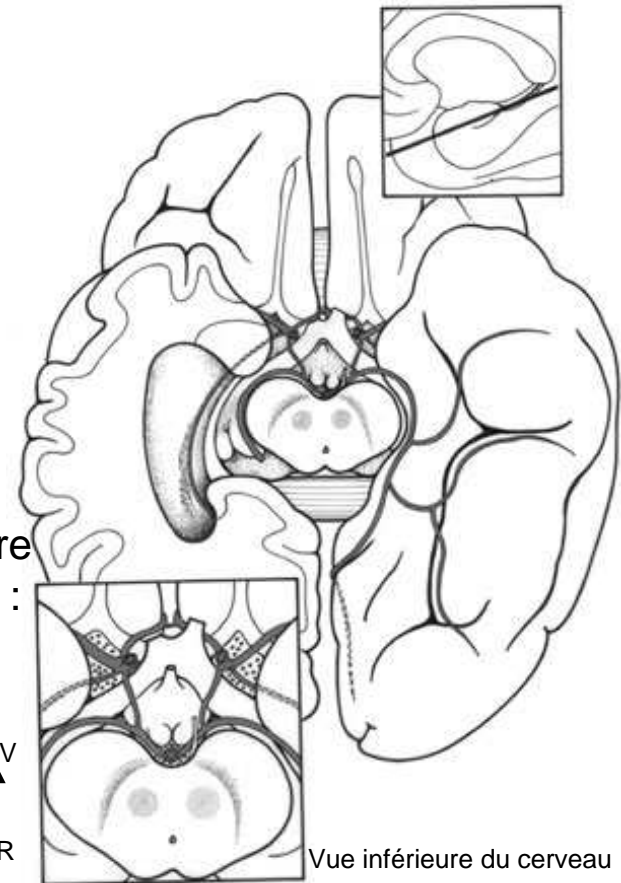
Vue inférieure du cerveau

- Artère communicante antérieure →
- Artères cérébrales antérieures →
- Artères communicantes postérieures →
- Artères cérébrales postérieures
- Sgt Précommunicant :
- ➡ Communicante basilaire
- Sgt post communicant :
- ➡ ACP
- variantes

AV
↑
AR

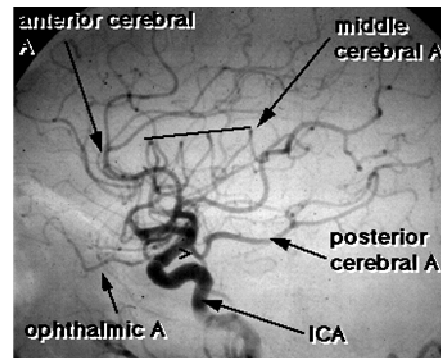
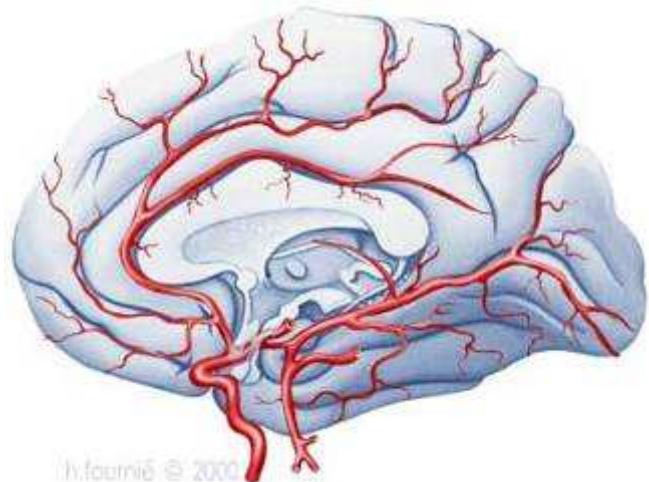
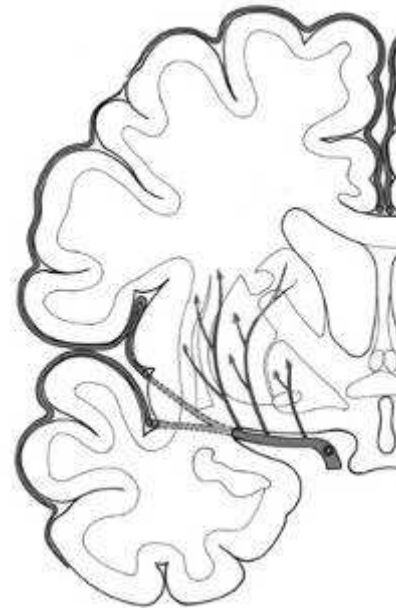
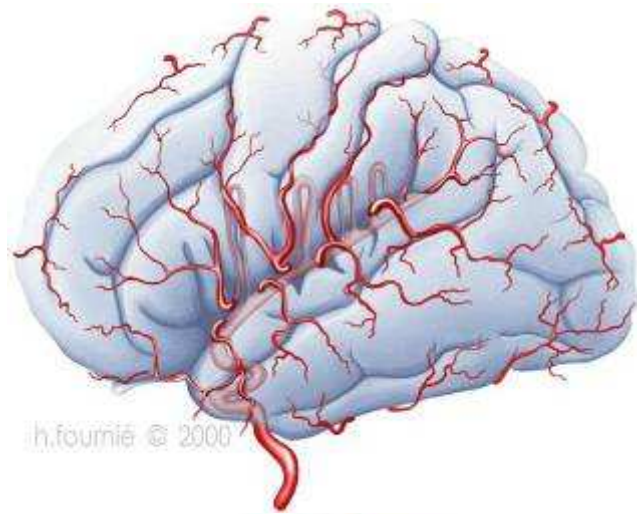


AV
↑
AR

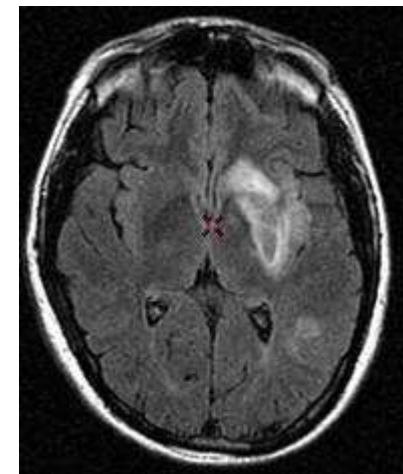
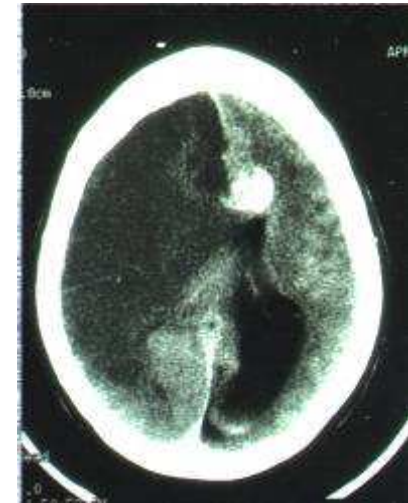


Vue inférieure du cerveau


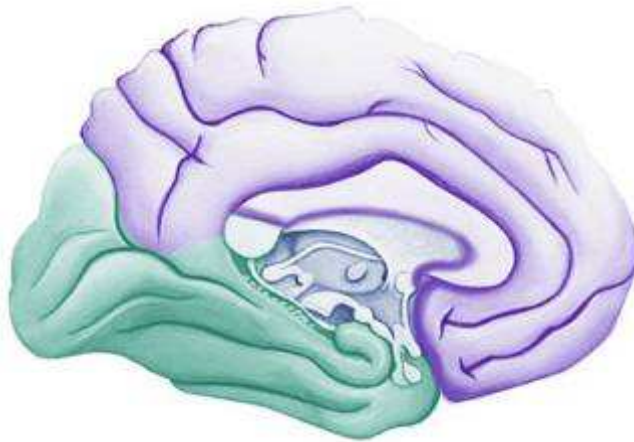
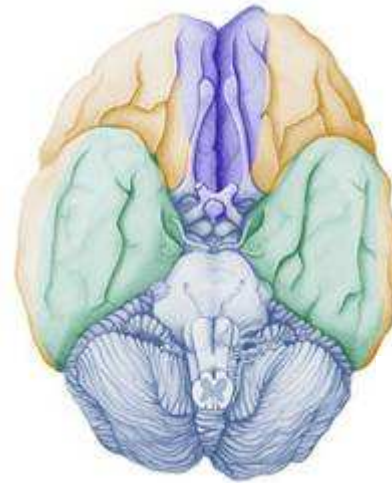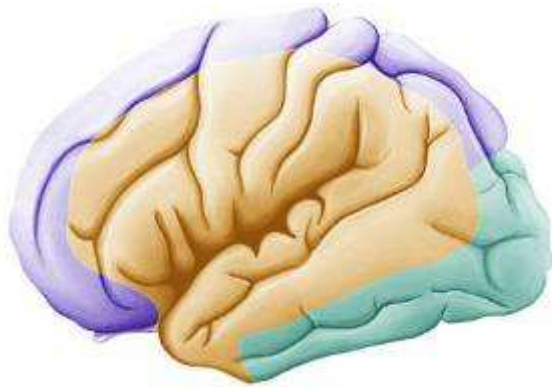
Artères cérébrales



> = posterior communicating A



Territoires vasculaires





Conclusion

- Système très spécifique
- Hiérarchisé mais distribué
- Compréhension spatiale et temporelle
- Évolution et embryologie

Bibliographie

- Site Neur@nat
- Carpenter, neuroanatomy – core text
- Duvernoy, le cerveau humain
- Khale, Neuroanatomie
- Barr, the human nervous system

- [L'ABC de l'AVC](#)
- [RADIOANATOMIE DE L'ENCEPHALE](#) M. BRAUN, J. ROLAND, L. PICARD CHU - NANCY
- [Functional Anatomy of Basal Ganglia](#) Adel K. Afifi, M.D. Gary Van Hoesen, Ph.D. Antoine Bechara, Ph.D., M.D. Robert Rodnitzky, M.D. Departments of Pediatrics, Neurology, Anatomy and Cell Biology University of Iowa, Iowa City, IA
- [BASIC SOMATOSENSORY PATHWAY](#) The Washington University School of Medicine Neuroscience Tutorial An illustrated guide to the essential basics of clinical neuroscience
- [The Fetal and Young Child Nervous System](#) The Story of the Development and Maldevelopment of the Brain Ronald A. Bergman, Ph.D. Professor of Anatomy Department of Anatomy University of Iowa College of Medicine Iowa City, Iowa

